

# Cephalometric Evaluation of Turkish Children With Class III Malocclusion in the Mixed Dentition

Ahmet Arif Celebi, DDS, PhD<sup>1\*</sup>; Enes Tan, DDS<sup>2</sup>; Ibrahim Erhan Gelgor, DDS, PhD<sup>3</sup>; and Tugba Colak, DDS<sup>4</sup>

## ABSTRACT

**Objective:** To investigate the cephalometric characteristics of Turkish children with Class III malocclusion and compare them with to those of children with clinically normal occlusion during the mixed dentition phase.

**Materials and Method:** Lateral cephalometric radiographs of 80 children with Class III malocclusion (mean age, 10.23 years) and 80 subjects with normal occlusion (mean age, 10.79 years) were examined for the study. Mean values of 13 linear and 21 angular cephalometric parameters were measured and compared.

**Results:** Sagittal skeletal measurements included SNB (Class III,  $81.82 \pm 4.26$ ; control group,  $74.5 \pm 3.86$ ;  $p < .001$ ), ANB (Class III,  $-2.35 \pm 2.02$ ; control group,  $2.4 \pm 1.17$ ;  $p < .0001$ ), Pg to Nasion vertical (Class III,  $-5.70 \pm 2.68$ ; control group,  $-9.60 \pm 3.21$ ;  $p < .05$ ), Wits appraisal (Class III,  $-5 \pm 4.57$ ; control group,  $-0.8 \pm 2.44$ ;  $p < .05$ ), Co-A (Class III,  $79.38 \pm 2.19$ ; control group,  $83.94 \pm 2.64$ ;  $p < .01$ ) and Co-Gn (Class III,  $105.7 \pm 2.04$ ; control group,  $102.4 \pm 1.15$ ;  $p < .05$ ). Vertical skeletal analysis included Gonial angle (Class III,  $132.6 \pm 7.15$ ; control group,  $122.1 \pm 6.6$ ;  $p < .01$ ), and S-Ar length (Class III,  $28.31 \pm 0.9$ ; control group,  $30.2 \pm 1.4$ ;  $p < .05$ ). Dentoalveolar measurements included U1 to SN (Class III,  $107.96 \pm 8.13$ ; control group,  $98.4 \pm 8.19$ ;  $p < .05$ ). Soft tissue measurements included soft tissue convexity (Class III,  $173.4 \pm 3.68$ ; control group,  $165.9 \pm 3.25$ ;  $p < .01$ ).

**Conclusion:** The findings of the study indicated that effective mandibular length was larger in Class III groups and effective maxillary length was smaller in Class III groups. (*Turkish J Orthod* 2013;26:85–91)

**KEY WORDS:** Cephalometrics, Class III malocclusion, Early treatment, Turkish children

## INTRODUCTION

Class III malocclusions are complex and difficult orthodontic problems to diagnose and treat. The prevalence of Class III malocclusion varies among different races and populations. A relatively high prevalence of Class III malocclusion has been observed in some Mediterranean and Middle Eastern populations;<sup>1–3</sup> however, the frequency of Class III malocclusion in these populations is less than in Asians of the Far East.<sup>4–6</sup> The prevalence has been reported as 13.0% in Japanese,<sup>4</sup> 14.5% in Chinese,<sup>5</sup> 19% in Korean,<sup>6</sup> 9.4% in Saudi Arabian,<sup>1</sup> and 3% in white populations.<sup>1</sup>

Determination of the anteroposterior jaw relationship is important for diagnosis during the pubertal

growth because the anteroposterior relationship between the upper and lower arches can worsen during puberty.<sup>7,8</sup> It is now well known that this malocclusion not only has a dental component but is also related to an underlying skeletal problem. Studies indicate that 63% to 73% of Class III malocclusions are skeletal types.<sup>9–11</sup> According to Guyer *et al.*,<sup>12</sup> 25% of a sample of patients with Class III malocclusion had pure maxillary skeletal retrusion, whereas fewer than 20% of the patients had pure mandibular prognathism. They found a combination of maxillary skeletal retrusion and

**\*Corresponding author:** Enes Tan, Kirikkale University, Department of Orthodontics, Kurtulus Mahallesi, 692. Sokak, No. 31, 71100 Merkez, Kirikkale, Turkey. Tel: +90-318-224 4927 E-mail: [dentistan@yahoo.com](mailto:dentistan@yahoo.com)

To cite this article: Celebi AA, Tan E, Gelgor IE, Colak T. Cephalometric evaluation of Turkish children with Class III malocclusion in the mixed dentition. *Turkish J Orthod.* 2013;26:85–91. (DOI: [http://dx.doi.org/10.13076/j.tjo.2013.26.02\\_85](http://dx.doi.org/10.13076/j.tjo.2013.26.02_85))

Date Submitted: September 2012. Date Accepted: January 2013.

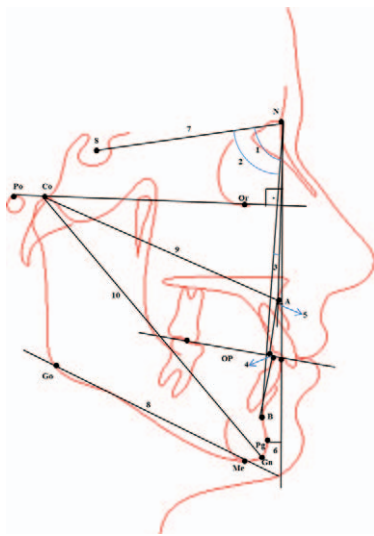
Copyright 2013 by Turkish Orthodontic Society

<sup>1</sup>Research Assistant, Kirikkale University, Faculty of Dentistry, Department of Orthodontics, Kirikkale, Turkey

<sup>2</sup>Research Assistant, Kirikkale University, Faculty of Dentistry, Department of Orthodontics, Kirikkale, Turkey

<sup>3</sup>Associate Professor and Head, Kirikkale University, Faculty of Dentistry, Department of Orthodontics, Kirikkale, Turkey

<sup>4</sup>Research Assistant, Kirikkale University, Faculty of Dentistry, Department of Orthodontics, Kirikkale, Turkey



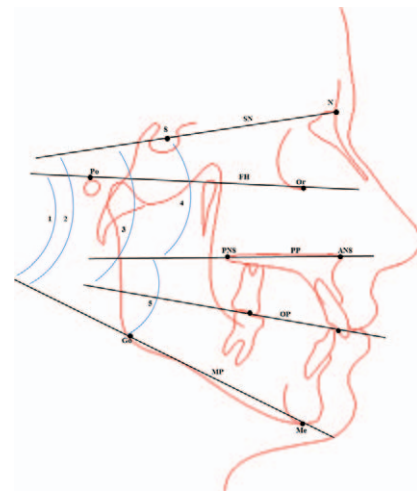
**Figure 1. Landmarks for sagittal cephalometric measurements.** (1) SNA: the anteroposterior position of the maxilla relative to the anterior cranial base, (2) SNB: the anteroposterior position of the mandible relative to the anterior cranial base, (3) ANB: obtained by subtracting SNB from SNA, (4) Wits appraisal: distance between A point and B point on the occlusal plane, (5) A point to Nasion vertical (A-NV): distance between the A point and N vertical to Frankfurt Horizontal line, (6) Pogonion to Nasion vertical (Pg-NV): distance between the Pogonion and N vertical, (7) Sella-Nasion (SN): distance from Sella to Nasion, (8) Mandibular length: distance from Gonion to Menton, (9) Co-A: effective length of maxilla, (10) Co-Gn: effective length of mandibula.

mandibular skeletal protrusion in approximately 22% of their patients with Class III malocclusion.<sup>12</sup>

Many studies describe the craniofacial features of Class III malocclusion in different ethnic groups in the literature.<sup>13–15</sup> The aim of this study was to identify the skeletal characteristics of craniofacial structures in a sample of Turkish children with Class III malocclusion in the mixed dentition phase.

## MATERIALS AND METHODS

The study group included 80 patients with skeletal Class III malocclusion (boys, 34; girls, 46; mean age, 10.23 years) and 80 patients with skeletal Class I malocclusion (boys, 32; girls, 48; mean age, 10.79 years) who were chosen from 2825 patients visited the Department of Orthodontics at Kirikkale Dental Faculty from 2004 to 2011. An independent *t* test was performed to determine the mean age for the Class III and Class I groups ( $p > 0.05$ ). Sixty-six boys (mean age, 10.64 years) and 94 girls (mean age, 10.34 years) were included in this study. All subjects and their families were living in Turkey (nonimmigrants), and the subjects had no prior

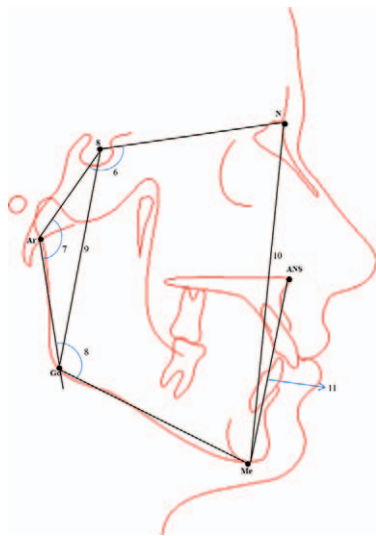


**Figure 2. Landmarks for vertical cephalometric measurements.** (1) FMA: the angle between the Frankfort horizontal (orbitale – porion) and mandibular plane, (2) SN plane-Mandibular plane angle (SN-GoGn): the inclination of the mandible to the anterior cranial base, (3) OP-SN: the inclination of the occlusal plane to the SN plane, (4) PP-SN: the angle of maxillary plane (ANS-PNS) inclination in relation to the anterior cranial base, (5) PP-MP: the angle of the maxillary plane (ANS-PNS) inclination in relation to the mandibular plane (GoGn).

histories of trauma, maxillofacial syndromes/anomalies, orthodontic treatment, or facial surgery.

Patients with Class III malocclusion were selected according to following criteria: (1) Class III relationship of the first molars, determined by clinical evaluation of each patient in centric relation to rule out functional Class III malocclusion; (2) crossbite of anterior teeth (more than 1 mm); (3) soft tissue facial convexity ( $>176$ ); and (4) no cleft palate or other craniofacial anomaly ( $ANB < 0$ ). The group with clinically normal occlusion showed the following: (1) excellent Class I molar relationships or less than half a cusp deviation, (2) normal overbite and overjet, and (3) straight to slightly convex profile. The lateral cephalometric radiographs were derived from the files of patients diagnosed as having skeletal Class III malocclusion and Class I malocclusion at the Orthodontic Department of Kirikkale University.

Lateral cephalometric radiographs were taken according to the following criteria: (1) natural head position with teeth in centric occlusion, (2) lips in the rest position, and (3) use of the same cephalostat system (PM 2002 EC Proline, Helsinki, Finland). Thirteen linear and 21 angular cephalometric parameters (Figs. 1 through 5) were measured on standardized lateral cephalometric radiographs by



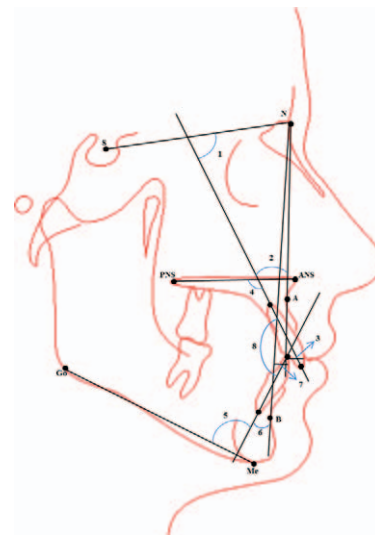
**Figure 3. Landmarks for vertical cephalometric measurements.** (6) Saddle angle (N-S-Ar): the angle between the anterior and posterior cranial base, (7) Articular angle (S-Ar-Go): the angle formed at the point of intersection of the S-Ar plane and the Ar-Go plane, (8) Gonial angle (Ar-Go-Me): the angle between the posterior border of the ramus (Ar-Go) and the mandibular plane (Go-Gn), (9) Jarabak ratio: ratio of total posterior (S-Go;9/NMe;10) to total anterior face height, (10) S-Ar: distance from point sella to point articulare, (11) ANS-Me: distance from the anterior nasal spine to menton.

the same researcher (A.C.). To test the reliability of the measurements, 45 randomly selected cephalograms were retraced 2 weeks later by the same orthodontist; all measurements were remeasured, and the reliabilities of the parameters were examined with analysis of variance index of reliability. The calculated reliabilities ranged from 87% to 99% and were statistically significant ( $p < .001$ ). There were no significant differences between the mean values of each parameter. This study was designed as a retrospective study, so an ethical approval was not needed.

All statistical analyses were performed with SPSS 16.0 software for Windows (SPSS, Chicago, IL, USA). After determining the distribution of the data and homogeneity of variance, an independent sample *t* test was used to assess the differences between the Class III group and the control group. Arithmetic means and standard deviations were calculated for each measurement. Statistical significance was indicated by a *p* value  $< .05$ .

**RESULTS**

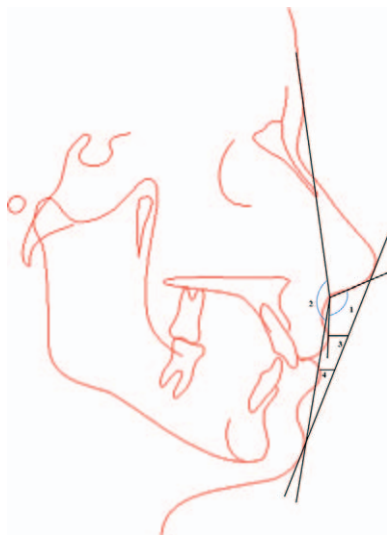Among the sagittal measurements, SNB, ANB, Pg to Nasion vertical, Wits appraisal, Co-A, and Co-Gn



**Figure 4. Landmarks for dentoalveolar cephalometric measurements.** (1) Maxillary incisor to SN plane (U1-SN): the angle between the long axis of the maxillary incisor to the SN plane, (2) Maxillary incisor to NA angle (U1-NA): the angle between the long axis of the maxillary incisor to the NA plane, (3) Maxillary incisor to NA plane (U1-NA): distance between the tip of the upper incisor and a line from Nasion to point A, (4) Maxillary incisor to palatal plane (U1-PP): the angle between the long axis of the maxillary incisor to the palatal plane, (5) Mandibular incisor to MP (L1-MP): the angle between the long axis of the mandibular incisor to the mandibular plane, (6) Mandibular incisor to NB angle (L1-NB): the angle between the long axis of the mandibular incisor to the NB plane, (7) Mandibular incisor to NB (L1-NB): distance between the tip of the mandibular incisor and a line from Nasion to point B, (8) Maxillary incisor to mandibular incisor (U1-L1): the angle between the long axis of the maxillary incisor to the long axis of the mandibular incisor.

were significantly different between the Class III and control groups ( $p < .001$ ;  $p < .0001$ ;  $p < .05$ ;  $p < .05$ ;  $p < .01$ , and  $p < .05$ , respectively) (Table 1). Even though subjects with Class III malocclusion had significantly smaller values for SNA, there was no statistically significant difference between the Class III and the control groups. The other sagittal parameters—A point to Nasion vertical, SN, and mandibular length—were not significantly different between the two groups.

No significant difference was observed between the groups for the vertical skeletal relationships except the Gonial angle ( $p < .01$ ) and S-Ar ( $p < .05$ ). Nevertheless, the ANS-Me length was longer in the Class III group than the control (Class I) group (Table 2). For the dentoalveolar relationships, only the maxillary incisor to SN plane (U1-SN) angle showed a statistically significantly difference between the groups ( $p < .05$ ) (Table 3). No significant



**Figure 5. Landmarks for soft tissue cephalometric measurements.** (1) Nasolabial angle (NLA): the angle formed by the intersection of the Columella tangent and the upper lip (UL), (2) Soft tissue facial convexity (SFC): the angle between the G'-Sn line and the Sn-Pog' line, (3) Upper lip to E plane: distance between the upper lip and a line from the tip of the nose to the end of the chin, (4) Lower lip to E plane: distance between the lower lip and a line from the tip of the nose to the end of the chin.

difference was observed between the groups regarding the soft tissue landmarks except for the soft tissue facial convexity ( $p < 0.01$ ) (Table 4).

## DISCUSSION

Determination of the skeletal and soft tissue norms of the Class III malocclusion have been studied in various populations.<sup>4,13-20</sup> However, most of the studies were performed in children with deciduous or permanent dentition; very few studies have examined children at the mixed dentition

stage.<sup>12,21</sup> On the other hand, there are several studies related to the treatment outcomes of patients with Class III malocclusion.<sup>22-27</sup>

In this study, cephalometric comparison of children with Class III malocclusion and children with normal occlusion who were in the same age group was performed. The aim of our study was to identify defining characteristics of Turkish children with Class III malocclusion in the mixed dentition phase.

Sagittal skeletal analysis presented highly significant differences between the groups in SNB, ANB, Pg-NV, Wits, Co-A, and Co-Gn measurements. All angular and linear measurements showing the sagittal position of the lower jaw had larger mean values except Co-A and ANB. These results indicated that effective mandibular length was larger in Class III groups and effective maxillary length was smaller in Class III groups.

To determine skeletal features of patients with Class III malocclusion, conjunctive use of the ANB angle and Wits appraisal was recommended.<sup>28,29</sup> A significant decrease of ANB and Wits appraisal between the Class III and Class I groups was also supported by the present study. According to a study performed in mixed dentition, the ANB angle was more suitable in determining Class III malocclusion than Wits appraisal.<sup>30</sup> In this study, Pg-NV was found to be significantly higher in all subjects with skeletal Class III malocclusion compared with subjects in the control group. Previous studies, done in the deciduous dentition phase, have reported that the angular and linear measurements of maxilla indicate that the Class III group had retrognathic maxillae and significantly larger mandibles than the Class I group.<sup>14,31,32</sup> In contrast, the results of our study revealed that there is no statistically significant

**Table 1.** Sagittal skeletal analysis of Class III and control groups

Measure Name	Class III Group		Control Group		p Value
	Mean	SD	Mean	SD	
SNA	75.17	4.23	77.56	3.94	0.07414
SNB	81.82	4.26	74.5	3.86	0.00080***
ANB	-2.35	2.02	2.4	1.17	0.00008****
WITS	-5	4.57	-0.8	2.44	0.01954*
A-NV	-5.1	2.42	-3.5	2.99	0.20528
Pg-NV	-5.7	2.68	-9.6	3.21	0.04823*
SN	67	2	69.9	2.42	0.13015
Mandibular length	71.6	1.5	70.5	3.12	0.52322
Co-A	79.38	2.19	83.94	2.64	0.00287**
Co-Gn	105.7	2.04	102.4	1.15	0.03748*

\*  $p < 0.05$ ; \*\*  $p < 0.01$ ; \*\*\*  $p < 0.001$ ; \*\*\*\*  $p < 0.0001$ .

**Table 2.** Vertical skeletal analysis of Class III and control groups

Measure Name	Class III Group		Control Group		p Value
	Mean	SD	Mean	SD	
FMA	29.20	3.91	25.20	4.68	0.05
SN-GoGn	33.90	4.28	34.40	4.64	0.81
OP-SN	18.20	2.25	20.80	3.94	0.15
PP-SN	8.70	4.00	9.70	4.21	0.59
PP-MP	23.40	5.09	21.60	5.21	0.54
N-S-Ar	126.20	5.45	122.60	5.48	0.27
S-Ar-Go	143.80	8.19	149.40	7.45	0.18
Ar-Go-Me	132.60	7.15	122.10	6.60	0.00312**
Sum of the posterior angles	402.60	11.85	394.20	12.24	0.17
Jarabak ratio	63.70	3.88	64.00	4.21	0.87
S-Ar	28.31	0.90	30.20	1.40	0.02735*
ANS-Me	61.24	2.47	60.20	1.95	0.06

\*  $p < 0.05$ ; \*\*  $p < 0.01$ .

difference in sagittal measurements of the maxilla between the groups.

No significant difference was observed between the two groups in the vertical skeletal analysis except for the Gonial angle and S-Ar length. An increase of this angle may indicate a future increase in total mandibular length in patients with Class III malocclusion. The Gonial angle is frequently larger in patients with Class III malocclusion.<sup>33-36</sup> However, Moua-keh<sup>13</sup> found no statistically significant difference between Class III and Class I groups in terms of Gonial angle, though S-Ar length was smaller in patients with Class III malocclusion. Condyle can be positioned upward in Class III groups.

Dentoalveolar analysis of this study revealed that the upper incisors were proclined in the Class III group. This finding is similar to findings of several studies,<sup>12,20,36</sup> Choi *et al.*<sup>14</sup> explained this situation as a dental compensation that can occur as early as the deciduous dentition years. In contrast, some investigators have reported that the upper incisors are

retroclined in Class III groups.<sup>13,32</sup> In our study, we found that the inclination of mandibular incisors was clinically normal. This is in disagreement with some authors who reported patients in which lower incisors were retroclined in the Class III malocclusion with permanent dentition.<sup>12,37,38</sup> It is in agreement, however, with a study of Syrian children with Class III malocclusion.<sup>13</sup>

Previous studies noted a significant decrease in soft tissue facial convexity in Class III malocclusion groups with primary dentition.<sup>14,39</sup> This is in an agreement with our study, which showed significant differences between the groups. The upper lip to E plane was also smaller in the Class III group, but the difference was not statistically significant.

### CONCLUSION

This study determined angular and linear skeletal, dental, and soft tissue cephalometric characteristics of a sample of Turkish children with Class III malocclusion

**Table 3.** Dentoalveolar analysis of Class III and control groups

Measure Name	Class III Group		Control Group		p Value
	Mean	SD	Mean	SD	
U1-SN	107.96	8.13	98.4	8.19	0.03332*
U1-NA angle	27.2	7.13	21.4	6.32	0.07033
U1-NA distance	5.1	1.72	4.8	2.44	0.75474
U1-PP	114.4	6.64	107.8	5.57	0.07722
L1-MP	89.1	7.31	91.5	7.47	0.47714
L1-NB angle	22.1	6.04	20.8	6.19	0.64059
L1-NB distance	3.7	1.82	3.5	1.43	0.78859
U1-L1	136.1	10.69	135.3	11.01	0.87094

\*  $p < 0.05$ .

**Table 4.** Soft tissue analysis of Class III and control groups

Measure Name	Class III Group		Control Group		p Value
	Mean	SD	Mean	SD	
NLA (°)	107.3	10.81	109.8	9.34	0.6859
SFC (°)	173.4	3.68	165.9	3.25	0.00167**
Upper lip to E plane (mm)	-4.5	3.13	-2.3	2.45	0.0975
Lower lip to E plane (mm)	-1.2	2.44	-1.4	1.57	0.8302

\*\*  $p < 0.01$ .

in the mixed dentition. Lateral cephalometric radiographs of 80 patients with Class III malocclusion were analyzed and compared with those of 80 patients with Class I normal occlusion. Class III groups had (1) a significantly increased SNB, Pg-NV, and Co-Gn; (2) a reduced ANB, Wits appraisal, Co-A, and S-Ar; (3) a significantly larger Gonial angle; (4) more proclined maxillary incisors; and (5) a notably increased soft tissue facial concavity.

## REFERENCES

1. Toms AP. Class III malocclusion: a cephalometric study of Saudi Arabians. *Br J Orthod.* 1989;16:201–206.
2. El-Mangoury NH, Mostafa YA. Epidemiologic panorama of dental occlusion. *Angle Orthod.* 1990;60:207–214.
3. Mouakeh M, Sulaiman M. Prevalence of malocclusion in a population of Syrian children and adults [in Arabic]. *Aleppo University Journal of Science Research.* 1996;23:17–22.
4. Lew KK, Foong WC. Horizontal skeletal typing in an ethnic Chinese population with true Class III malocclusions. *Br J Orthod.* 1993;20:19–23.
5. Chan GK. Class 3 malocclusion in Chinese (Cantonese): etiology and treatment. *Am J Orthod.* 1974;65:152–157.
6. Lim H, Yoon Y, Kim K. A study of the characteristics of craniofacial skeleton on orthognathic surgical cases with skeletal Class III malocclusion. *Korean J Orthod.* 1998;28:189–201.
7. Nanda RS, Ghosh J. Longitudinal growth changes in the sagittal relationship of maxilla and mandible. *Am J Orthod Dentofacial Orthop.* 1995;107:79–90.
8. Ishikawa H, Nakamura S, Kim C, Iwasaki H, Satoh Y, Yoshida S. Individual growth in Class III malocclusions and its relationship to the chin cap effects. *Am J Orthod Dentofacial Orthop.* 1998;114:337–346.
9. Kapust AJ, Sinclair PM, Turley PK. Cephalometric effects of face mask/expansion therapy in Class III children: a comparison of three age groups. *Am J Orthod Dentofacial Orthop.* 1998;113:204–212.
10. Susami R. A cephalometric study of dentofacial growth in Class III subjects with anterior crossbite. *Nihon Kyosei Shika Gakkai Zasshi.* 1967;26:1–21.
11. Chang HP. Components of Class III malocclusion in Taiwanese. *Kaohsiung J Med Sci.* 1985;1:144–155.
12. Guyer EC, Ellis EE III, McNamara JA Jr, Behrents RG. Components of Class III malocclusion in juveniles and adolescents. *Angle Orthod.* 1986;56:7–30.
13. Mouakeh M. Cephalometric evaluation of craniofacial pattern of Syrian children with Class III malocclusion. *Am J Orthod Dentofacial Orthop.* 2001;119:640–649.
14. Choi HJ, Kim JY, Yoo SE, Kwon JH, Park K. Cephalometric characteristics of Korean children with Class III malocclusion in the deciduous dentition. *Angle Orthod.* 2010;80:86–90.
15. Ishii N, Deguchi T, Hunt NP. Craniofacial differences between Japanese and British Caucasian females with a skeletal Class III malocclusion. *Eur J Orthod.* 2002;24:493–499.
16. Sanborn RT. Differences between the facial skeletal patterns of Class III malocclusion and normal occlusion. *Angle Orthod.* 1955;25:208–222.
17. Baik HS, Han HK, Kim DJ, Proffit WR. Cephalometric characteristics of Korean Class III surgical patients and their relationship to plans for surgical treatment. *Int J Adult Orthodon Orthognath Surg.* 2000;15:119–128.
18. Ngan P, Hagg U, Yiu C, Merwin D, Wei SH. Cephalometric comparisons of Chinese and Caucasian surgical Class III patients. *Int J Adult Orthodon Orthognath Surg.* 1997;12:177–188.
19. Nezu H, Nagata K, Yoshida Y, Kosaka H, Kikuchi M. Cephalometric comparison of clinical norms between the Japanese and Caucasians. *Nihon Kyosei Shika Gakkai Zasshi.* 1982;41:450–465.
20. Namankani EA, Bukhary MT. Cephalometric craniofacial characteristics of a sample Saudi female adults with Class III malocclusion. *Saudi Dent J.* 2005;17:88–100.
21. Baccetti T, Reyes BC, McNamara JA Jr. Gender differences in Class III malocclusion. *Angle Orthod.* 2005;75:510–520.
22. McNamara JA Jr. An orthopedic approach to the treatment of Class III malocclusion in young patients. *J Clin Orthod.* 1987;21:598–608.
23. Nartallo-Turley PE, Turley PK. Cephalometric effects of combined palatal expansion and facemask therapy on Class III malocclusion. *Angle Orthod.* 1998;68:217–224.
24. Baccetti T, McGill JS, Franchi L, McNamara JA Jr., Tollaro I. Skeletal effects of early treatment of Class III malocclusion with maxillary expansion and face-mask therapy. *Am J Orthod Dentofacial Orthop.* 1998;113:333–343.
25. Ngan P. Biomechanics of maxillary expansion and protraction in Class III patients. *Am J Orthod Dentofacial Orthop.* 2002;121:582–583.

26. Kilicoglu H, Kirlic Y. Profile changes in patients with Class III malocclusions after Delaire mask therapy. *Am J Orthod Dentofacial Orthop.* 1998;113:453–462.
27. Hagg U, Tse A, Bendeus M, Rabie AB. Long-term follow-up of early treatment with reverse headgear. *Eur J Orthod.* 2003;25:95–102.
28. Bishara SE, Fahl JA, Peterson LC. Longitudinal changes in the ANB angle and Wits appraisal: clinical implications. *Am J Orthod.* 1983;84:133–139.
29. Rushton R, Cohen AM, Linney AD. The relationship and reproducibility of angle ANB and the Wits appraisal. *Br J Orthod.* 1991;18:225–231.
30. Iwasaki H, Ishikawa H, Chowdhury L, Nakamura S, Iida J. Properties of the ANB angle and the Wits appraisal in the skeletal estimation of Angle's Class III patients. *Eur J Orthod.* 2002;24:477–483.
31. Tollaro I, Baccetti T, Bassarelli V, Franchi L. Class III malocclusion in the deciduous dentition: a morphological and correlation study. *Eur J Orthod.* 1994;16:401–408.
32. Chang HP, Kinoshita Z, Kawamoto T. Craniofacial pattern of Class III deciduous dentition. *Angle Orthod.* 1992;62:139–144.
33. Alling CC. Mandibular prognathism. *Oral Surgery.* 1961;14(suppl):3–22.
34. Maj G, Luzi C, Luchese P. Skeletal and dental behaviorism Class II division 1 and in Class III cases. *Trans Eur Orthod Soc.* 1958;34:88–89.
35. Graber TM. *Current Orthodontic Principles and Techniques.* Philadelphia, PA: Saunders; 1969.
36. Battagel JM. The aetiological factors in Class III malocclusion. *Eur J Orthod.* 1993;15:347–370.
37. Ellis E III, McNamara JA Jr. Components of adult Class III malocclusion. *J Oral Maxillofac Surg.* 1984;42:295–305.
38. Graber TM, Rakosi T, Petrovic A. *Dentofacial Orthopedics With Functional Appliances.* St Louis, MO: Mosby; 1997.
39. Rak D. Cephalometric analysis in cases with Class III malocclusions. *Stomatol Glas Srb.* 1989;36:277–287.