



REVIEW

Recent Photography Trends in Orthodontics

Hakkı Yılmaz, Fundagül Bilgiç, Özlem Akıncı Sözer

Department of Orthodontics, Mustafa Kemal University School of Dentistry, Hatay, Turkey

ABSTRACT

The use of photographic documentation is essential procedure in orthodontic diagnosis and treatment planning. These records are also required for legal protection. Digital technology is gaining importance for creation of photographic recording. In this article, we want to give an overview of standardization and the latest developments in the photographic field in orthodontic clinics.

Keywords: Photograph, digital, orthodontics

113

Digital Photography in Dentistry

Digital photography offers many advantages to clinicians, such as being quick and easy to obtain, eliminating costs related to capturing photos, providing easy arrangement and archiving, and offering ready communication between clinicians as well as simple preparation process for presentations and publications.^{1,2} Based on these reasons, digital photography is widely used today.

However, many orthodontics experience problems in recording or converting photographs to be used for presentations. Thus, we should have thorough knowledge of computer software, nomenclature about photography and programs used for presentations.³

Digital Camera

There are two types of digital cameras, including auto-focus cameras (Point&Shot) and digital single lens reflex cameras (DSLR). DSLR cameras are preferred while capturing orthodontic pictures.^{4,5} DSLR cameras are highly compatible and adaptive. Choice of camera is determined by factors such as easy use, durability, weight, price, protection against environmental factors (water and dust), quality of lens, and availability of sensor cleaning.⁶

Resolution

Digital camera resolution is a factor associated with the quality of image obtained (Figure 1). Although high resolution is desirable, it has some disadvantages, including greater file size, longer time for uploading or printing image, and higher costs. Some factors should be taken into account while making decision to use high- or low-resolution camera. If we show images to patients on the monitor or we send images to a colleague as printed material, it is important how the recipient requests the images. One should request high-resolution in wide screen while others request low-resolution in a smaller monitor.⁷

Bit and Byte

Digital data are recorded by using binary encoding system. The smallest encoding unit is a bit, which is either 0 or 1. A byte is used to measure file sizes (kilobyte, megabyte, gigabyte, etc.), which consists of eight bits. Image files encompass binary data for each pixel and its color. Thus, more colors require higher number of bits. Location of pixels is coupled to bits in the data. In other words, digital images can be termed as images coupled to bits (Figure 2).³

File Size

Size of digital images is determined by number of total pixels and color intensity. Number of pixels depends on size, width, and height of image. It is important to know that resizing image by dragging alone does not change file size. When photograph is re-opened in the monitor, the pixels on the monitor are narrowed or widened, but the number of pixels is preserved in the original file. Image is always converted to original size.³

Focal Length

Focal length should be adjusted accurately to prevent disruption in perspective, especially in facial photographs. In frontal photographs, shorter focal length will lengthen nose while longer focal length will produce contrary effect. This can be exemplified by capturing an object by a 35-mm wide-angle or 135-mm telephoto lens. In the former, the object will appear far while object will appear closer. The optimal distance in the optic system of human is equivalent to 90-mm lens. At the same time, this is the focal length used for capturing portrait photos. In facial photographs, approximately 90 mm of focal length should be used to avoid distortion.⁷

Snapshot

Snapshot is the term that determines how long digital sensor or object will expose to light. Opening of diaphragm and closing of snapshot give us time of light exposure. Snapshot is expressed as partitions of a second such as 1/8 or 1/250.⁴ Increasing snapshot allows capturing instantaneous movements. When capturing intraoral photos, acuity loss caused by hand tremor will decrease if high-velocity shutter is present. In addition, low-velocity shutter cause prolonged activation of digital image sensor; thus, image appears brighter. On the contrary, darker images are obtained in high-velocity shutters.⁸

Light Source

If sufficient illumination is requested, a combined light source with lens should be used. It is of importance to position the flash according to the lens for capturing optimal intraoral photos. When the flash is attached over the lens or any side of the lens, a shadow will occur at the contralateral side. In a case of a flash attached to right side, a right buccal image will be perfect, while there will be shadow at the left molar region. However, shadowing will be avoided by using a ring flash attached to the lens.⁷

Special Buccal Cheek Retractors

It is recommended to use double-ended cheek retractors in clinical photography.^{4,5,9} There are two types of retractor set. One set has regular and small-sized retractors (small set), while the other set has narrow and wide ends (wide set). The small set is used for intraoral occlusal photos, while the wide set is used to capture frontal and buccal photos. It is required to use optimal set in order to obtain wide and sharp photos of the working area.⁴




Figure 1. An example of the kind of resolution




Figure 2. An example of the kind of byte




Figure 3. Photograph of the stainless steel mirrors

Photography Mirrors

Mirrors can be manufactured in various forms such as silver-coated glasses or polished stainless steel mirrors (Figure 3).^{4,5} Condensation causes problems in all intraoral photos captured using mirrors. To avoid condensation, mirror should be heated and the patient should hold the breath for 10 seconds.^{4,9} The mir-

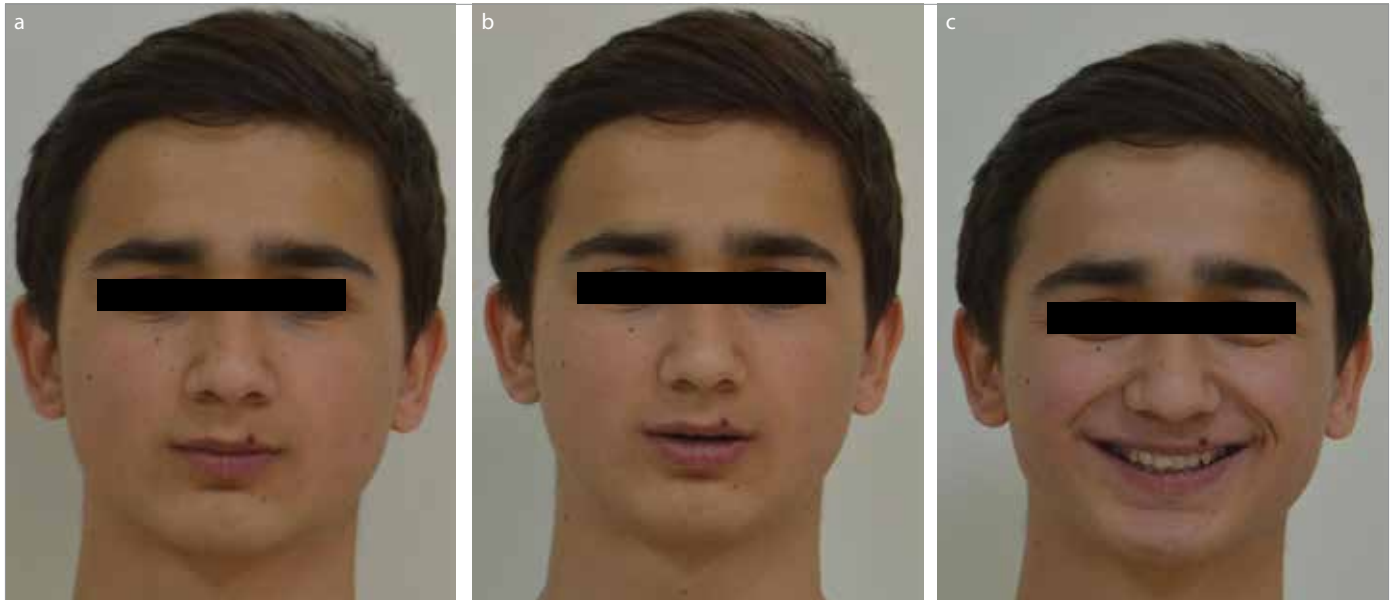

Figure 4. a-c. Frontal images of the patient

ror should be positioned accurately for accurate visualization. If mirror is at the correct position, palatal surfaces of maxillary incisors or lingual surfaces of mandibular incisors will be seen in the photo. If labial surfaces of incisors are seen in the photo, this indicates insufficient mouth opening by the patient.⁵

When glass mirrors are compared to polished metal mirrors, better photos are captured using glass mirrors.^{4,5} In addition, glass mirrors are more stable against scratching. If silver coating is beneath the glass, a second image or phantom images can be produced. To avoid this, silver coating should be on the frontal surface of the mirror.⁹

Extra-Oral Images

Portrait mode is recommended for optimal facial photo.^{4,5} Landscape mode will cause prominent background and thus a smaller face.¹⁰ Frame of picture should involve jaw and neck of the patient. Vertical positioning of the camera should be fixed using a tripod, and there should be a distance of 7 feet or 2 meters between the camera and the patient.^{4,11} If possible, the photographer and the patient should be at the same eye level. It is recommended to use dark blue or white background for optimal visualization of the face. Diaphragm opening should be at minimum. F8 is the value generally used.⁴

Frontal Full Face

The patient should be at neutral head position and look at camera. For frontal imaging, 4 different photos are captured (Figure 4a-c).^{4,10}

a) Frontal resting: Lips and mandible should be at resting position.^{4,10} While capturing this image, the patient's head should not be skewed, face should be directed to the camera, and the image should be captured while midline is positioned perpendicular to the camera. Pupil line should be parallel to the ground.^{4,9,10} If

possible, pupils can be constricted using dental light in order to minimize formation of red eye.⁹

b) Centric occlusion with closed lips: While capturing this image, maxillary and mandibular teeth should be at centric occlusion position with closed lips. This position is important for lip tension and esthetics. In addition, it also shows lip insufficiency and mental muscle activity.¹⁰

c) Frontal smile: In this position, teeth and gum are visualized while smiling.¹⁰ This photo also captures soft tissue compatibility during smile.⁴ Since smiling is a dynamic condition, video can also be captured.¹²

d) Close-up smile: This photo is recommended for detailed analysis of smiling position.¹⁰

Oblique (3/4; 45°)

While capturing oblique images, the patient is rotated to 45° right and 3 different photos are captured.

a) Oblique resting: It is useful for mid-facial assessments, particularly in nasal deformities.¹⁰ In this image, it is difficult to assess jaw and neck, gonial region, and mandibular length. It is focused on lip fullness and the vermillion line. Both right and left oblique images should be captured in patients with asymmetry.¹⁰

b) Oblique smile: In oblique smile images, the relationship between occlusal plane and lip curvature is assessed. In addition, posterior inclination caused by posterior maxilla, superior inclination caused by anterior maxilla or both (in other words occlusal inclination) can be assessed.¹⁰

c) Close-up smile: It better demonstrates the relationship among tooth, jaw, and lips when compared to extra-oral oblique photos.¹⁰

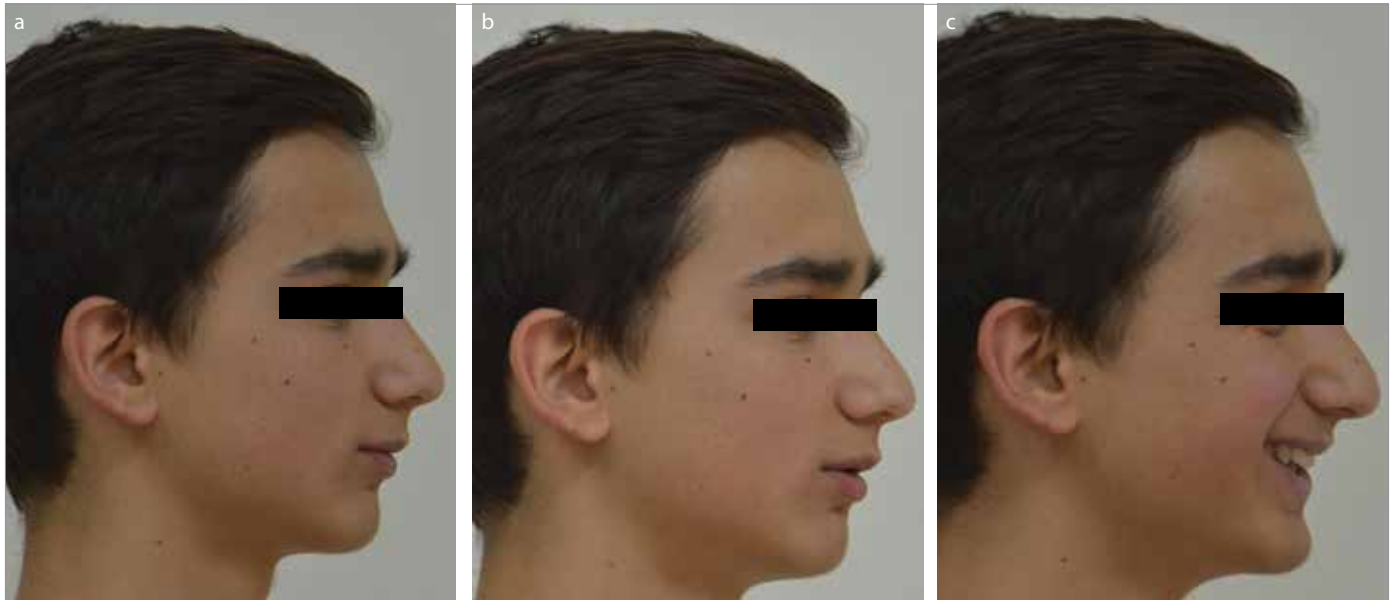

Figure 5. a-c. Profile photograph of the patient while the head is at the neutral position and the Frankfort horizontal plane is parallel to the ground

116

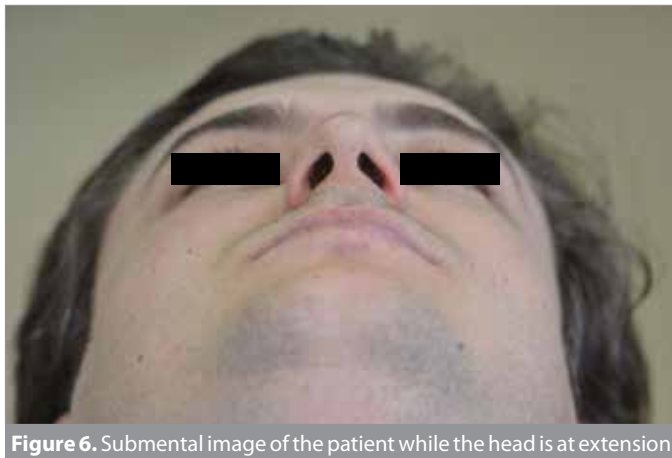

Figure 6. Submental image of the patient while the head is at extension

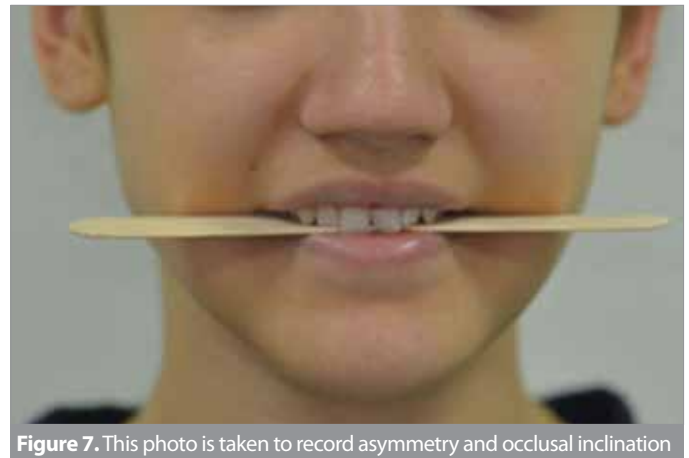


Figure 7. This photo is taken to record asymmetry and occlusal inclination

Profile

Profile photos should be taken while the head is at the neutral position and the Frankfort horizontal plane is parallel to the ground (Figure 5a-c).^{13,14} The most common way of maintaining a neutral head position is looking in a mirror. The lower margin of the photo should involve the superior margin of the scapula and contours of the jaw and neck, while the superior margin should be above the head and the lateral margin should be beyond the nose.^{9,10} Some clinicians may exclude the posterior aspect of the head from the picture. Extra images at background can be safely excluded from the image as they add unnecessary information to the image. In patients with long hair, hair should be picked up behind ears.^{9,10} Images captured with inaccurate head position will provide erroneous information about the skeleton.^{4,9,15} Only one profile photo compatible with cephalometric radiograph should be taken. In patients with facial asymmetry, both right and left profile photos should be taken.⁹ Dental light should be used when the flash is insufficient for illumination.^{9,13}

a) Profile resting: This photo is taken while the lips are at resting position while the teeth have centric relationship.

b) Profile smile: This photo demonstrates the inclination of maxillary incisors. This is an important point for patients regarding esthetic concerns but orthodontists do not necessarily recognize it. This is caused by lack of reflection inclination of maxillary incisors seen in clinic to cephalometric radiograph in some cases.¹⁰

c) Centric occlusion: The photos at centric occlusion position are also taken in patients with discrepant centric relationship and centric occlusion.¹⁵

d) Maximal protrusion: The photos are taken from patients with mandibular retrognathia, class 1 canines, or maximum protrusion.¹⁵

Submental Image

This photo is taken to record asymmetry in patients with mandibular asymmetry. Submental image is captured while the head is at extension (Figure 6).^{10,16}

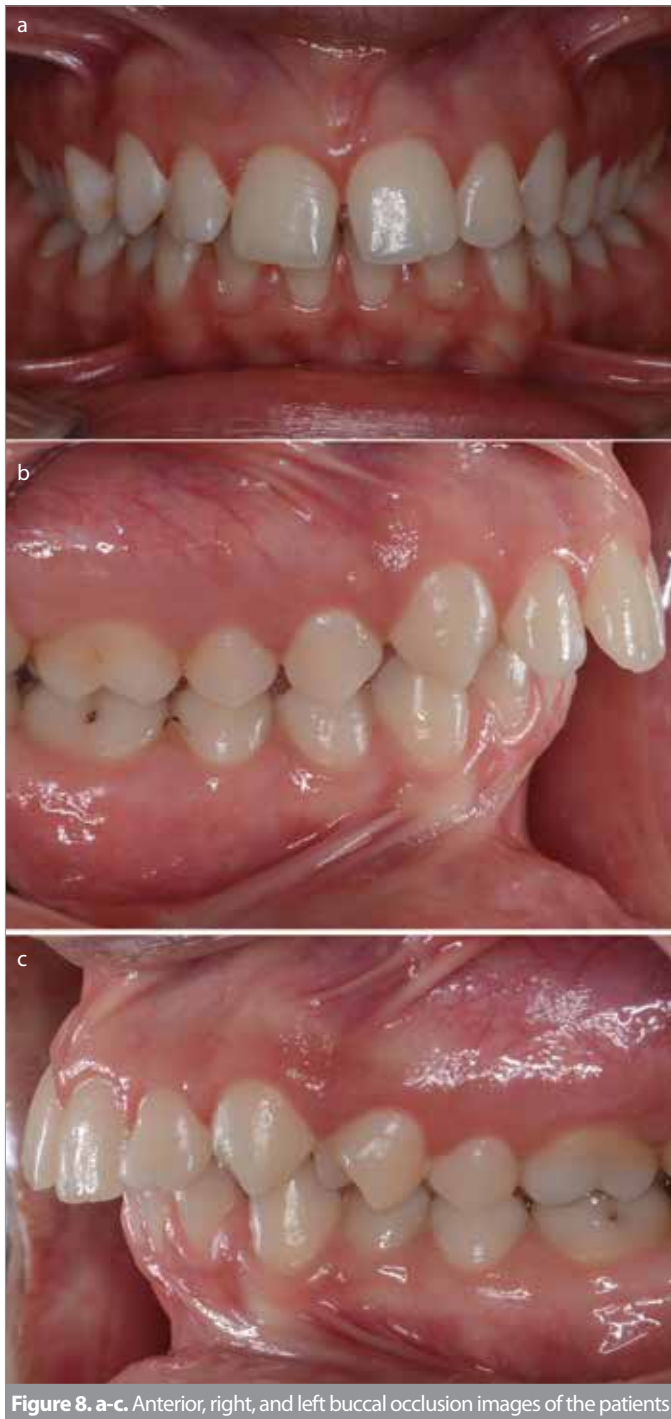

Figure 8. a-c. Anterior, right, and left buccal occlusion images of the patients

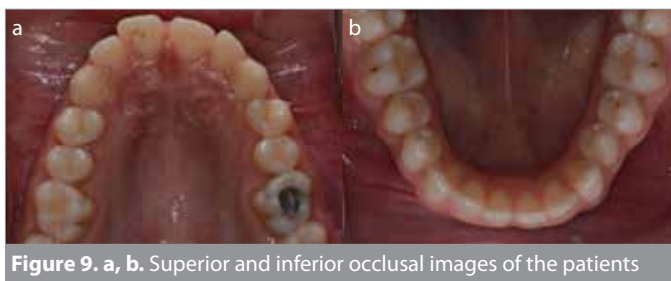


Figure 9. a, b. Superior and inferior occlusal images of the patients

Occlusal Inclination

This photo is taken to record asymmetry and occlusal inclination. The patient bites a thin rod or spatula while the image is captured. A wooden tongue depressor can be used (Figure 7).¹⁷

Intraoral Photos

Oral cavity demonstrates a stable structure in patients who achieved oral hygiene.¹⁸ Thus, photos taken become more reliable. Overall, 5 photos are taken, including frontal, right, and left buccal occlusal and inferior and superior occlusal images. If there is a discrepancy between centric relationship and centric occlusion, they should be captured separately.¹⁰ The tongue should be at the back position, the teeth should be closed, and the occlusal plane should be parallel to the ground while taking intraoral photos. The occlusal plane should divide the photo into 2 equal parts.⁹

Aperture value (F value) should be at maximum while taking intraoral photos. This provides increased depth. In these photos, white spot lesions, hyperplastic areas, and gingival clefts are recorded. The lesions caused by orthodontic therapy become apparent by this way.^{9,19} All records should be routinely documented for accurate diagnosis.

Anterior Image

Anterior image should be captured as being perpendicular to facial midline by using upper frenulum as the guide (Figure 8). This photo alone is unreliable as the dental midline can be shifted to either side due to malocclusion. Stretching sulcus is important to obtain complete and sharp images. Higher F values should be used to obtain maximal depth in the areas captured.⁴

Right and Left Buccal Occlusion Images

In direct shots, buccal occlusion images are obtained using cheek retractors (Figure 8), while side mirrors are used during indirect shots. Direct shots could be preferred for comfort and due to the ability to obtain occlusal data from cast models.¹⁰ Camera should be placed perpendicular to the canine premolar region for optimal visualization of relations among buccal segments. In photos taken from the anterior at 45°, class 2 relationship can appear as class 1.^{4,20} Before capturing the image, the assistant pulls the retractor distally by 4-5 mm. Then, the image is captured as distal side of first molar tooth being visualized. The margins of the photo consist of the medial part of central incisors and the distal part of the first molar teeth.⁹

Superior Occlusal Image

The patient's head is positioned to maximum extension. Small-end retractors are placed to the lips and rotated to the midline. Then, the lips are retracted anterolaterally.^{4,5,9} The mirror is inserted into the mouth and tilted downwards. The posterior part of the dentition can be best visualized in this way (Figure 9). It is recommended to use the mid-palatal suture as guide. Retractors and fingers should not be seen in the photo.⁴

Inferior Occlusal Image

The patient should move his/her tongue backwards to prevent interruption of teeth imaging (Figure 9).⁴ In the absence of cast models, discrepancy between tooth size and arc size can be mea-

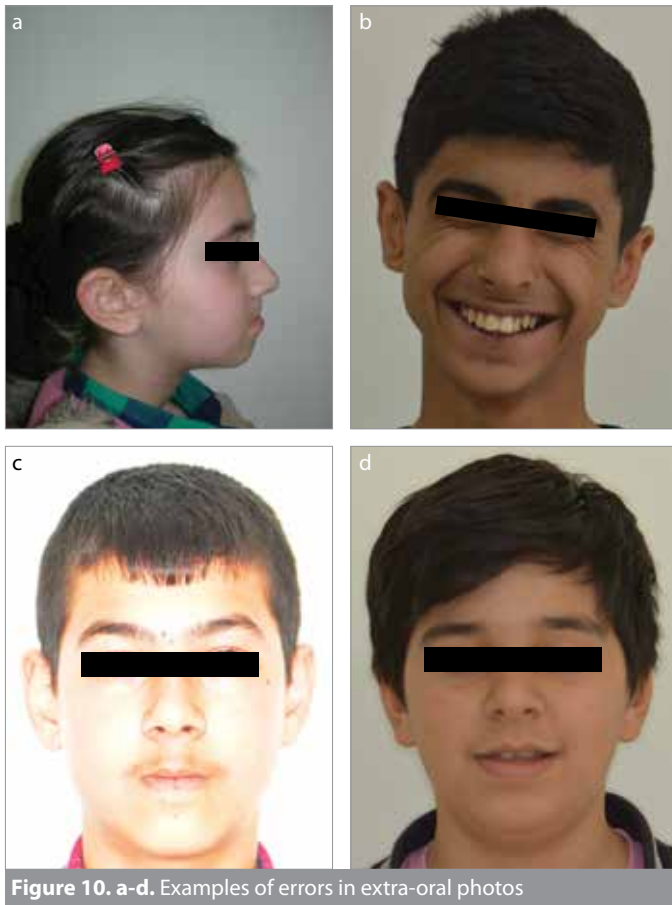

Figure 10. a-d. Examples of errors in extra-oral photos

sured by using superior and inferior occlusal images. In addition, it helps to determine amount of extraction and anchorage areas that needed to be supported.²¹

Common Errors in Capturing Images

Correct orientation of the camera is important. Extra-oral photos are taken using a tripod. For intraoral photos, camera should be adjusted as being perpendicular to the reference point.^{4,5} Portrait mode should be used for capturing extra-oral photos, whereas landscape or macro modes should be used for capturing intraoral photos.^{4,5,9} In addition, 35-mm cameras are important to compare extra-oral, intraoral, and mirror images captured at varying time points and to perform fixed magnification.^{5,9,22,23}

Errors in Extra-Oral Photos

Based on a previous study of the photos taken in orthodontics clinics, 60% are taken by the orthodontist, 35% are taken by the assistant, and only 5% are taken by professional clinical photographers.²⁴ During capturing images, errors such as those due to position of camera, weak focus, darkness, or excessive brightness can occur (Figure 10a-d). Other errors caused by position of patient include those resulted from difference of height between patient and photographer, failure to adjust Frankfort plane or neutral head position, hair masking the ears, closed eyes, or smooth tissues at undesired position.

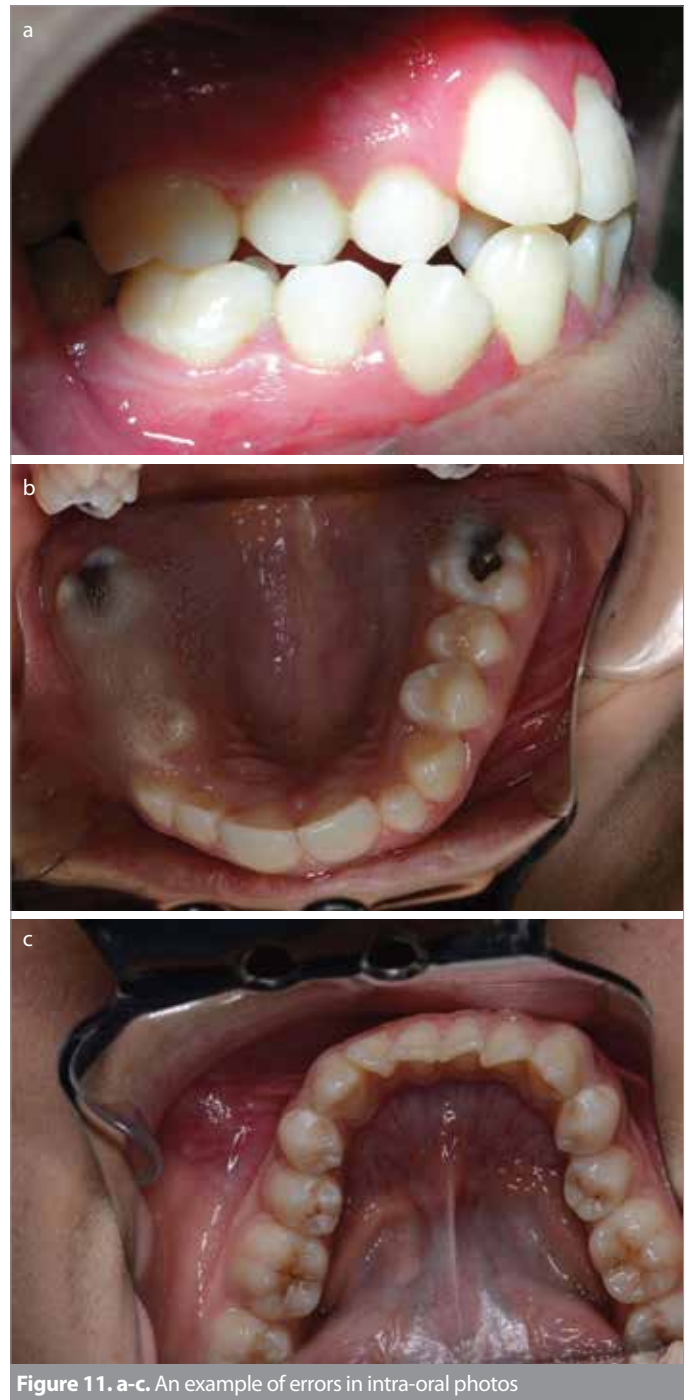

Figure 11. a-c. An example of errors in intra-oral photos

Errors in Intraoral Photos

It is more difficult to capture intraoral images than extra-oral photos. Good retraction is needed to obtain desired photos. Wide retractors are used for this purpose. In addition, effective communication is important to capture intraoral images. If we have an assistant who works correctly, we should maintain communication by positive phrases whereas constructive criticisms should be employed if he/she needs to be more careful.

High-quality occlusal photos rely on effective communication. If a patient fails to open his/her mouth sufficiently, the patient should be informed about importance of sufficient mouth open-



Figure 12. Clipping errors include lack of desired area on the image

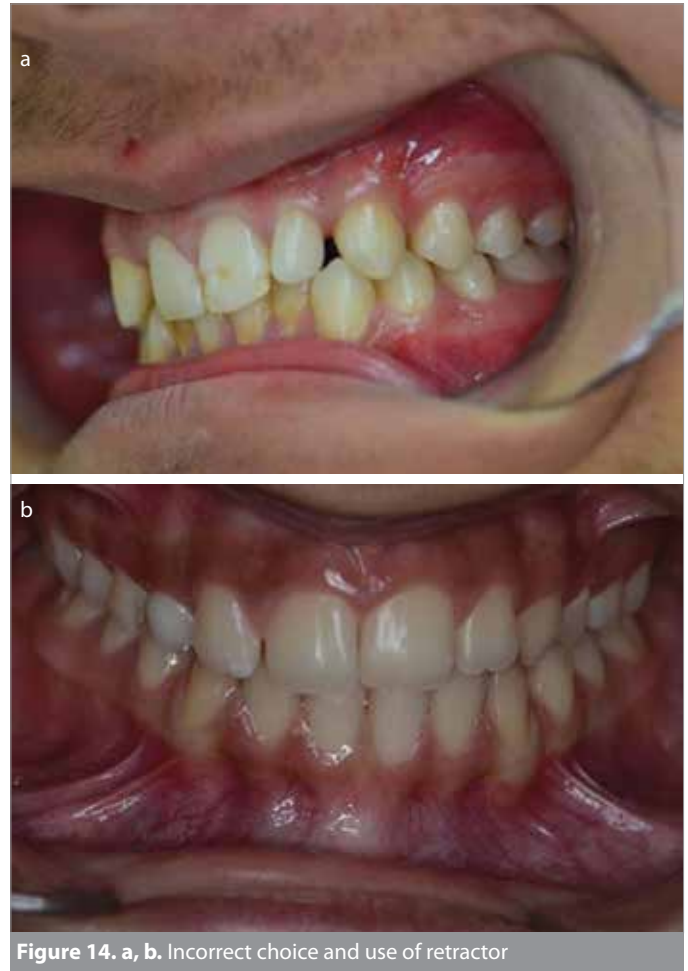

Figure 14. a, b. Incorrect choice and use of retractor

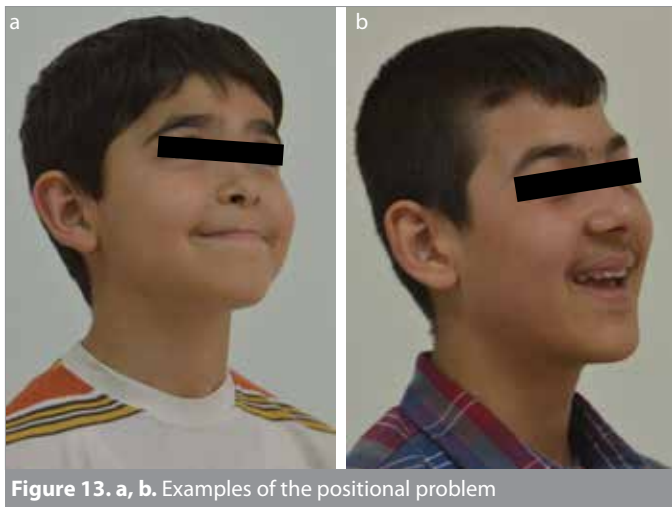


Figure 13. a, b. Examples of the positional problem

ing. Communication with the patient by the orthodontist is a better approach.²⁵

Other potential problems include excessive bubbles of saliva, mist on the mirror, dark buccal passages, insufficient elimination of tongue, and failure to visualize distal side of first molar teeth or blockage of area interested by retractor (Figure 11a-c).²⁶

Problems Related to Digital Camera

Field of depth

The diaphragm opening controls both amount of light that the object is exposed to and image sharpness. When the diaphragm opening is reduced, larger areas can be visualized with increased sharpness. The field visualized by acceptable sharpness is termed as field of depth. Field of depth decreases by increasing diaphragm opening (F: 1.2–1.5); in addition, sharpness of the areas out of focus is also decreased. Field of depth is associated to extent of focal area, magnification, and diaphragm opening. Field of depth distributes one-third anterior and two-third posterior to focal plane. Insufficient field of depth can be improved by using larger diaphragm opening.⁹ In professional cameras, diaphragm openings as low as F: 32 are available. When focus is placed on distal to lateral incisor, a sharp image can be obtained from brackets of incisors to brackets of premolar teeth.

Clipping errors

Clipping errors include lack of desired area on image or those resulted from insufficient manipulation of photo on computer (Figure 12). This error can be prevented by including a larger area than desired into the image and clipping unnecessary areas on the computer.²⁵

Auto-Focus problems

Options of automatic or manual focusing are available in most digital cameras. Manual focusing is preferred due to some reasons. One should focus on lateral teeth when using commercial cameras and on canines when using professional cameras.

In intraoral photos, auto-focus problems occur due to lack of sharp demarcations within the mouth. Attempts to capture images fail as auto-focus light turns off (which generally appears as a green light) when focusing occurs.⁹ In clinics, manual focusing is used to address such problems. Availability of focusing throughout the lens in state-of-art cameras make it easier to focus. The distance between the patient and the camera is adjusted by the clinician in commercial models. For example, the focal length is adjusted to 20 cm manually and the photo is taken when sharpest focusing is achieved by moving camera slowly back and forth.⁹ It should be focused on the lower eyelid in frontal, oblique, and profile photos. It is intended that the area from ears to the nose should be within the field of depth.

Charge Coupled Device (CCD) Problems

Dust can accumulate on CCD of the camera as lenses on digital cameras do not need to change. The dust accumulation appears as small, black spots when intraoral and extra-oral images are evaluated. In SLR cameras, CCD can be cleaned by using optic cleaning solutions since it is possible to reach CCD.⁹

Positional problems

Most errors in profile photos occur due to the posture of patient. Tilting head anteriorly or posteriorly as well as different magnification values cause erroneous assessment in skeletal and morphological manner (Figure 13a, b).^{9,15}

Inclined occlusal plane, incorrect choice, and use of retractor are most common mistakes in anterior and buccal shots within mouth (Figure 14a, b).⁹ Other errors include failure to suck excessive saliva or to retract tongue and alginate on teeth. In addition, molar relationship can be assessed inaccurately if photos of premolar and canine region aren't taken by an angle of 90° in buccal shots.⁹

Dynamic Records

Another method to evaluate the facial norms is to take the dynamic recording of smile and speech with digital videography. Using of this method is widespread in the smile position rather than the rest position.²⁷ Schabel et al.²⁸ reported that digital videography method gives us a lot of information for assessing the dynamic properties of smile, but the standard digital photography method is still sufficient for evaluation of smiles after treatment.

3D Imaging Systems

From the past to the present, photography and cephalometric radiographs have been used to evaluate facial soft tissue. However, these methods have still some deficiencies. Some variables such as the distance between the subject and the camera, the camera angle, position of the head and settings of the camera may impact the assessments in the evaluation with photos. Also, cepha-

lometric radiographs have some disadvantages such as superimposition, distortion, magnification, errors in patient positioning, and radiation exposure. More importantly, when evaluations were carried out by cephalometric radiographs, three-dimensional (3D) human face would be reduced to two-dimensions (2D), and depth is lost. Because of all these negative situations, 2D imaging systems began to give way to the 3D system.

3D imaging systems are effective, fast, and non-invasive methods that require minimal patient cooperation. 3D imaging systems are used to determine the norms of facial soft tissue in populations, monitor growth and development, evaluate treatment outcomes, and perform soft tissue simulations. Records obtained by noninvasive and nonionized 3D imaging systems can be repeated in the desired period. With these advantages, 3D imaging systems are particularly preferred in growth and development studies.^{29,30}

While the assessments performed by the 2D system are made along horizontal and vertical directions, 3D images can be carried out along the x (horizontal size), y (vertical dimension), and z (anteroposterior dimension and depth) axes. In the assessment with 2D imaging system, measurements calculated bird's-eye distance between the 2 shortest coordinates. In 3D imaging systems, the distance between two points can be measured either with bird's-eye or surface topography. In addition, angular, proportional, and volumetric measurements can be made, while we can create hundreds of colorful facial maps and image simulations.³¹⁻³³

Laser Scanning

Laser scanning 3D imaging technology is used for facial soft tissue imaging. The image is taken at 0.5-mm sensitivity and for 8–10 seconds. The length of time obtaining images may cause stabilization distress and loss of the image clarity, especially in infants and young patients.³⁴ Patients close their eyes while the image is taken, so the stabilization of landmarks can be disrupted, in particular around the eyes. A flash in the background may occur in surfaces without soft tissue, and some difficulties may be encountered in identifying landmarks depending on the surface color. Even white light laser applications may lead to some deficiencies for capturing accurate color in the tissue surface.³⁵

Stereophotogrammetry

Stereophotogrammetry is an imaging system that transforms the 2-dimensional images obtained by 2 synchronized camera device to the 3D images with the help of computers, and makes processed the complex algorithms process. The system consists of two synchronized cameras angled at 150° and mounted in a frame 50 cm from within.³⁵ Time of the image capture is up to 1.5 milliseconds, and the processing time is approximately 30 seconds. The short image capture time especially causes a great advantage for the patient and the physician. High image quality and noninvasive and ionized nature of imaging are advantages. It is a more rapid method according to the laser scanning system, and there are no safety concerns with the laser scanning system in this system.

3Dmd Imaging Systems

Recently, especially in the dental clinic, 3dmd (3Dmd, Atlanta, Ga, USA) face system, which is a stereophotogrammetry system, has been started to be used frequently. 3dmd is a surface imaging system and designed to display a 3D human face. The system provides exact size image with face morphology and linear, angular, and volumetric measurements of the human face. Advanced photography speed with high resolution eliminates image distortion caused by patient movement.³⁶

CONCLUSIONS

Orthodontics and other fields of dentistry should follow technological advances strictly in order to use in practice. Capturing high-quality photos is one of these practices, comprising an important topic in all fields of dentistry. In parallel, photography has become an optional subject in some universities in our country. When advantages of photos captured in the clinic are considered,

- 1) Routine documentation is achieved,
- 2) Photos can be used at presentation and comparison of cases,
- 3) It is important to compare data during long-term follow-up,
- 4) Standardization of records is important to obtain reliable results, and for comparison of outcomes
- 5) Images captured before, during, and after treatment provide legal protection when needed.

REFERENCES

1. Gallegos AG. Enhancing interprofessional communication through digital photography. *J Calif Dent Assoc* 2001; 29: 752-7.
2. Smith RV. The digital camera in clinical practice. *Otolaryngol Clin North Am* 2002; 35: 1175-89. [CrossRef]
3. Swartz M L. Managing digital images. *Am J Orthod Dentofacial Orthop* 2000; 118: 354-8. [CrossRef]
4. Samawi SS. A short guide to clinical digital photography in orthodontics. SDOC, 2008.
5. Mizrahi E. *Orthodontic pearls: A selection of practical tips and clinical expertise*. London: Taylor and Francis, 2004. [CrossRef]
6. Bister D, Mordarai F, Aveling RM. Comparison of 10 digital SLR cameras for orthodontic photography. *J Orthod* 2006; 223-30. [CrossRef]
7. Scholz RP. Considerations in selecting a digital camera for orthodontic records. *Am J Orthod Dentofacial Orthop* 1998; 114: 603-5. [CrossRef]
8. Uçar Fİ, Uysal T, Bengi AO. Standardization of records in orthodontics. *Turkish Journal of Orthodontics* 2010; 23: 86-105. [CrossRef]
9. McKeown HF, Murray AM, Sandler PJ. How to avoid common errors in clinical photography. *J Orthod* 2005; 32: 43-54. [CrossRef]
10. Graber T. *Orthodontics: Current Principles and techniques*. 4th ed. St. Louis, Elsevier Mosby, 2005.
11. Sarver DM, Johnston MW, Matukas VJ. Video imaging for planning and counselling in orthognathic surgery. *J Oral Maxillofac Surg* 1988; 46: 939-45. [CrossRef]
12. Ackerman MB, Ackerman J. Smile analysis and design in the digital era. *J Clin Orthod* 2002; 36: 221-36.
13. Graber TM. Patient photography in orthodontics. *Angle Orthod* 1946; 16: 17-43.
14. Williams R. Positioning and lighting for patient photography. *J Biol Photogr* 1985; 53: 131-43.
15. Claman L, Patton D, Rashid R. Standardized portrait photography for dental patients. *Am J Orthod Dentofacial Orthop* 1990; 98: 197-205. [CrossRef]
16. Sarver DM, Ackerman MB. Dynamic smile visualization and quantification: Part 1. Evolution of the concept and dynamic records for smile capture. *Am J Orthod Dentofacial Orthop* 2003; 124: 4-12. [CrossRef]
17. Larrabee W, Maupin G, Sutton D. Profile analysis in facial plastic surgery. *Arch Otolaryngol Head Neck Surg* 1985; 111: 682-7. [CrossRef]
18. Surdacka A, Strzykala K, Rydzewska A. Changeability of oral cavity environment. *Eur J Dent* 2007; 1: 14-7.
19. Bengel W. Standardization in dental photography. *Int Dent J* 1985; 35: 210-7.
20. Sandler J, Murray A. Current products and practise clinical photographs-the gold standarts. *J Orthod* 2002; 29: 158-67. [CrossRef]
21. Ramsden P. *Learning to teach in higher education*. London & New York, Routledge, 1992. [CrossRef]
22. Nayler JY. Clinical photography. *J Posgrad Med* 2003; 49: 256-62.
23. Benson PE, Stephen R. A critical appraisal of measurement of the soft tissue outline using photographs and video. *Eur J Orthod* 1997; 19: 397-409. [CrossRef]
24. Sandler PJ, Murray AM. Clinical photographs-the gold standard. *J Orthod* 2002; 29: 158-67. [CrossRef]
25. Sandler J, Dwyer J, Kokich V, McKeown F, Murray A, McLaughlin R, et al. Quality of clinical photographs taken by orthodontists, Professional photographers, and orthodontic auxiliaries. *Am J Orthod Dentofacial Orthop* 2009; 135: 657-62. [CrossRef]
26. McKeown HF, Murray AM, Sandler PJ. How to avoid common errors in clinical photography. *J Orthod* 2005; 32: 43-54. [CrossRef]
27. Nooreyazdan M, Trotman CA, Faraway JJ. Modeling facial movement: II. A dynamic analysis of differences caused by orthognathic surgery. *J Oral Maxillofac Surg* 2004; 62: 1380-6. [CrossRef]
28. Schabel BJ, Baccetti T, Franchi L, McNamara JA. Clinical photography vs digital video clips for the assessment of smile esthetics. *Angle Orthod* 2010; 80: 490-6. [CrossRef]
29. Al-Azemi R, Al-Jame B, Artun J. Lateral cephalometric norms for adolescent Kuwaitis: soft tissue measurements. *Med Princ Pract* 2008; 17: 215-20. [CrossRef]
30. Murakami D, Inada E, Saitoh I, Takemoto Y, Morizono K, Kubota N, et al. Morphological differences of facial soft tissue contours from child to adult of Japanese males: a three-dimensional cross-sectional study. *Arch Oral Biol* 2014; 59: 1391-9. [CrossRef]
31. Farronato G, Salvadori S, Nolet F, Zoia A, Farronato D. Assessment of inter- and intra-operator cephalometric tracings on cone beam CT radiographs: comparison of the precision of the cone beam CT versus the latero-lateral radiograph tracing. *Prog Orthod* 2014; 6: 15:1.
32. Chiu MH, Tan CT, Huang SF, Chen JA. Microsc Microanal. High Resolution Full-Field Reflection-Type Three-Dimensional Angle-Deviation Microscope with Nonlinear Error Compensation 2015; 21: 778-87.
33. Sforza C, Elamin F, Rosati R, Lucchini MA, Tommasi DG, Ferrario VF. Three-dimensional assessment of nose and lip morphology in North Sudanese subjects with Down syndrome. *Angle Orthod* 2011; 81: 107-14. [CrossRef]
34. Gwilliam JR, Cunningham SJ, Hutton T. Reproducibility of soft tissue landmarks on three-dimensional facial scans. *Eur J Orthod* 2006; 28: 408-15. [CrossRef]
35. Hajeer MY, Ayoub AF, Millett DT, Bock M, Siebert JP. Current Products and Practices: Applications of 3D imaging in orthodontics: Part I. *J Orthod* 2004; 31: 62-70. [CrossRef]
36. Lübbers HT, Medinger L, Kruse AL, Grätz KW, Obwegeser JA, Matthews F. The influence of involuntary facial movements on craniofacial anthropometry: a survey using a three-dimensional photographic system. *Br J Oral Maxillofac Surg* 2012; 50: 171-5. [CrossRef]