



## REVIEW

# Applications of Cone Beam Computed Tomography in Orthodontics: A Review

Aditya Tadinada<sup>1</sup>, Alana Marczak<sup>2</sup>, Sumit Yadav<sup>3</sup>, Padma M Mukherjee<sup>4</sup>

<sup>1</sup>Division of Oral and Maxillofacial Radiology, University of Connecticut, School of Dental Medicine Farmington, Connecticut, USA

<sup>2</sup>School of Dental Medicine, University of Connecticut, Farmington, Conn, USA

<sup>3</sup>Division of Orthodontics, University of Connecticut, School of Dental Medicine Farmington, Connecticut, USA

<sup>4</sup>Division of Orthodontics, Rutgers School of Dental Medicine, Newark, NJ, USA

## ABSTRACT

Cone Beam Computed Tomography (CBCT) is being extensively used in orthodontics for diagnostic and treatment planning, especially in complex clinical conditions. The objective of this study was to review the English language literature for current applications and trends of CBCT in orthodontic diagnosis and treatment. Several electronic databases were searched with the primary words: "orthodontics and radiography" and "cone beam computed tomography" or "CBCT." Abstracts that appeared to fulfill our inclusion criteria were selected, and the complete articles were obtained. Twenty-eight abstracts initially met our search criteria, and 12 were selected for the review. Ten articles were later added to the list after hand searching the references. It was concluded that there is a need for prospective randomized clinical trials to evaluate the risk/benefit ratio of CBCT, such as higher cost, greater risk for radiation dose (compared to digital panoramic and cephalograms) versus superior diagnosis and treatment outcomes.

**Keywords:** CBCT, orthodontic applications

## INTRODUCTION

The corner stone to successful orthodontic treatment is accurate diagnosis and fundamentally sound treatment planning. Conventional two-dimensional (2D) radiographic imaging techniques (panoramic radiography, cephalograms, occlusal, and periapical radiographs) have been traditionally used in orthodontics for several decades. The use of conventional, multi-slice medical computed tomography (CT) for three-dimensional (3D) imaging in routine dentistry has been limited owing to its high cost and radiation dose. Recent advances in the field of 3D imaging have led to the development of newer modalities that have tried to overcome some of the problems of conventional multi-slice CTs. The research and development in this field has largely led to a reduction in the radiation dose and improved spatial resolution. The quest to develop a 3D imaging modality for the craniofacial complex has led to the development of the Cone Beam Computed Tomography (CBCT). CBCT has emerged as a powerful tool for imaging the craniofacial complex because of its low cost, high spatial resolution, reduced radiation exposure, and smaller foot print in comparison to the multi slice medical CT. CBCT is fast becoming the imaging modality of choice in clinical cases requiring extensive 3D views, especially in patients with craniofacial asymmetries (1), TMJ disorders (2,3), tooth impactions (4) and respiratory issues involving the sinuses and airways (5). Several case reports and a few studies advocate the use of CBCT in routine orthodontic diagnosis and treatment planning (4,6). Studies have also demonstrated that panoramic radiographs, which were once considered the standard of care for pre-treatment orthodontic diagnosis, should be questioned for their reliability (1). CBCT is being considered for three-dimensional radiography in dentistry because of its high-resolution imaging and excellent diagnostic ability (7,8). In the past, studies have investigated the effects of skeletal expansion by measuring dental casts or 2D cephalometric images (9,10). CBCT now affords 3D visualization and quantitative analysis of skeletal versus dental effects of maxillary expansion. Utilizing the 3D imaging ability of CBCT, precise linear and angular measurements that aid the clinician in lo-

calizing areas of malformation such as clefts and other pathology (11) are now possible. Computerized navigation systems have proven to be valuable tools in several surgical procedures (12,13). Although long-term and randomized clinical trials are needed to confirm their value, this technique is gaining popularity in optimizing the placement of skeletal anchorage devices and implants (14-17). However, there appears to be a lack of awareness and some controversy regarding the use of CBCT for routine orthodontic treatment because of its inherent limitations, e.g., radiation dose (18,19). Some of the proven advantages of CBCT (20,21) and its increasing patient popularity have led to a rising trend towards incorporating CBCT for all orthodontic patients. However, as responsible health care providers, we must not neglect fundamentals such as the ALARA principle - "as low as reasonably achievable." It is necessary that all applications and limitations of this new technique be addressed systematically and critically. Currently, we do not have sufficient randomized clinical studies that can be utilized to evaluate the use of CBCT in routine orthodontic diagnosis and treatment. Therefore, a meta-analysis to evaluate the current status of CBCT applications related to orthodontics could not be performed. This study was conducted to review the literature and to assess the current applications, advantages and limitations of CBCT in orthodontics. This study also aims to help general dentists and orthodontists identify cases that will benefit from the use of CBCT based on the current evidence and avoid unnecessary radiation exposure, especially for the younger patient population, when possible.

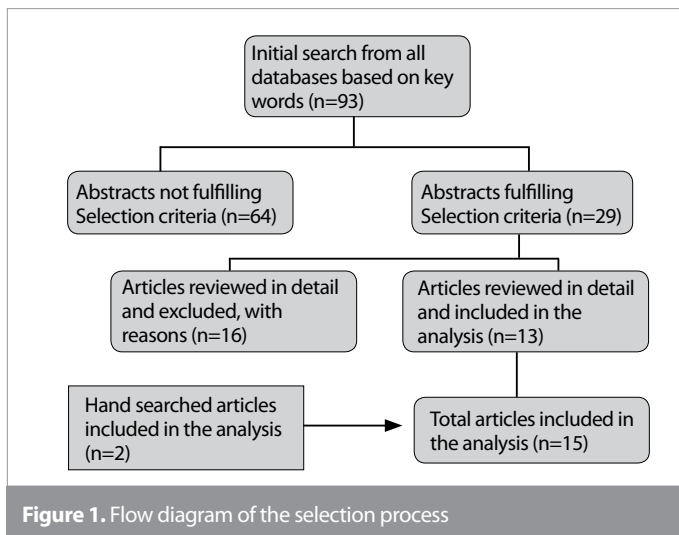
## METHODS

The following English language electronic databases were searched for this review: PubMed, Medline, Scopus, and Web of Science from 1990 to the first week of November 2014. The primary search words used were "orthodontic radiography" and "cone beam computed tomography" or "CBCT." Only original research articles in English were selected for this study. Case reports, reviews, and personal communications were not included in this study. The following inclusion criteria were applied for abstracts: "craniofacial imaging," "radiograph," "orthodontic diagnosis," "CBCT applications," and "orthodontic treatment." The reference lists of the selected articles were also searched for additional articles that were relevant to this study and that may have been missed in the database searches using key words. Two researchers (P.M. and A.T.) determined the article eligibility from the databases by reading the title and abstracts. If the abstracts met the selection criteria, the full articles were obtained. If the data from the abstract were unclear, the full articles were reviewed. The two researchers read the abstracts and checked for articles in English. The following criteria to determine eligibility were used: 1) did the study match the title, 2) was the methodology sound, and 3) were the conclusions based on the results. In addition to the initial criteria, the full articles were later subjected to additional search mechanisms that included work that researched the applications of CBCT in orthodontics but did not show up in the initial search. The researchers made this final selection independently, and their results were later combined. Inconsistencies were addressed through discussion.

**Table 1.** Database search results

Database	Keywords	Results
Pub Med	Orthodontic radiography and Cone Beam CT or CBCT	31
Web of Science	Orthodontic radiography and cone beam CT or CBCT	3
Scopus	Orthodontic radiography and cone beam CT or CBCT	15
Web of knowledge	Orthodontic radiography and cone beam CT or CBCT	16
Medline	Orthodontic radiography and cone beam CT or CBCT	28

CT: computed tomography; CBCT: cone beam computed tomography



**Figure 1.** Flow diagram of the selection process

## RESULTS

Utilizing the search criteria described above, we found a total of 92 articles from the various search engines. The 39 articles from PubMed included all the articles found in the other search engines. Table 1 lists the search results from all the search engines utilized in this study. After the initial search, 28 abstracts met our search criteria. The complete articles were obtained, critically reviewed, and 12 were selected for the review. Ten articles were later added to the list after hand searching the references. Figure 1 is a flow diagram of the selection process. Key information from these articles is illustrated in Table 2.

### Accuracy of Measurements

Periago et al. (22) conducted an observational cross-sectional *ex vivo* experiment. The group measured the accuracy of linear measurements on 23 human skulls, comparing the direct measurements on the skulls to the measurements made on CBCT images. They concluded that although most linear measurements between cephalometric points from the 3D volumetric surface renderings generated from CBCT scans may be statistically significantly different from the anatomic dimensions, they are clinically accurate for craniofacial diagnostic purposes. Stratemann et al. (23) evaluated the accuracy of the linear distances between

**Table 2.** Summary of the selected articles

Category	Author	Study Design	Major Conclusions
Measurement Accuracy	Periago et al. (22)	23 dry human skulls with 14 indelible craniometric landmarks were imaged with CBCT to determine the linear accuracy of CBCT measurements.	Linear measurements between cephalometric landmarks on 3D volumetric renderings are sufficiently clinically accurate for craniofacial analysis.
	Stratemann et al. (23)	One skull with chromium steel balls embedded at 32 cranial and 33 mandibular landmarks was scanned with 2 different CBCT systems to determine the accuracy of the linear measurements between anatomic landmarks.	Volumetric data rendered with New Tom and Hitachi MercuRay provided highly accurate data compared to the gold standard of physical measurements from the skulls, with less than 1% relative error.
Craniofacial Anatomy	King et al. (14)	Evaluated vertical bone volume in the para-median palate of 183 patients ages (10-19) as a potential site for orthodontic implant placement using CBCT.	CBCT provided an accurate assessment of the entire bone volume to evaluate potential implant sites in the para-median palate. >90% of boys and girls had a sufficient vertical bone height for a 3 mm implant in the area 4 mm distal & 3 mm lateral to the incisive foramen.
Craniofacial Malformations	Hamada et al. (27)	17 bone bridges after grafting (n=13) in cleft lip and palate patients were examined by conventional radiography and a dental 3D-CT imaging system.	CBCT is beneficial for clinical assessment of alveolar bone grafting before and after installation of dental implants or orthodontic treatment of the cleft-adjacent teeth.
Impactions	Walker et al. (29)	Impacted canines from 27 patients were imaged with CBCT to evaluate their spatial relationship.	CBCT images can demonstrate the presence or absence of canines, follicle size, and inclination of the long axis, relative buccal and palatal positions, and bony coverage over the tooth, adjacent structures, and dental development. 3D imaging is valuable in cases with impacted canines and improves diagnosis and orthodontic treatment planning.
	Liu et al. (4) 2008	The locations of 210 impacted maxillary canines were analyzed using CBCT images.	There is great variation in maxillary canine impactions, and resorption of neighboring incisors is a common feature.
Maxillary Expansion	Garrett et al. (32)	Evaluated 30 orthodontic patients who required rapid maxillary expansion using CBCT.	Skeletal expansion had a triangular pattern with a wider base in the anterior region, and age had no significant effect on the amount of expansion.
	Rungcharassaeng et al. (31)	30 orthodontic patients requiring rapid maxillary expansion were imaged with CBCT, and the bone thickness, inter dental distance, and angle were analyzed.	Average expansion=4.96 mm, duration=4.4 weeks, rate of expansion=0.83 mm, and retention time=3.6 weeks. Age, appliance expansion, initial buccal bone thickness and differential expansion correlate with buccal bone thickness and dental tipping, while the rate of expansion and retention time showed no significant association.
Mini-screw and Implant Studies	Maverna et al. (6)	Evaluated 72 patients, ages 20–44 years, and studied the palatal bone thickness to determine the most ideal location for implant placement using CBCT.	The thickest bone was 4 mm behind and 6 mm lateral to the incisive foramen. The bone progressively thinned out from the anterior to the posterior region. Areas on the side of the median palatal suture appear to have adequate bone thickness for mini-screw placement.
	Kim et al. (35)	Evaluated the surgical positioning of orthodontic mini-implants with guides prepared on models using CBCT.	Using CBCT images as a guide for implant placement makes the procedure safer and can prevent inter-radicular damage compared to conventional guides.
	Nickenig et al. (17)	Assessed the reliability of implant placement after virtual planning of the implant positions using CBCT data and surgical guide templates.	Implant placement after virtual planning of the location using CBCT data and surgical templates can be reliable for pre-operative assessment of implant size, position, and anatomical complications. It is also indicative in cases of flapless surgery.
Advantages of CBCT	Korbmacher et al. (11)	68 CBCT and 15 CT images with orthodontic indications were compared with each other and conventional radiographs.	In complex orthodontic cases like cleft lip & palate, patients with mental disabilities, syndromes, and surgical intervention requiring 3D imaging CBCT should be preferred over CT. CBCT gave more

**Table 2.** Summary of the selected articles (Continue)

	Holberg et al. (21)	The image quality of CBCT and dental CT of 417 teeth and surrounding structures was examined.	information about impacted teeth and osseous structures in the clefts, but it did not sufficiently depict cartilaginous structures or add information about the TMJ.  The advantages of CBCT were reduced metal artifacts, lower radiation dose, and superior demonstration of skeletal malocclusions in comparison to dental CT. The dental CT had better image quality. Bone and surrounding structures, PDL space (80%), enamel-dentin interface, ankylosis and pulp cavity edges were more sharply demonstrated on dental CT.
Radiation Dose	Silva et al. (19)	The radiation dose of digital panoramic & cephalometric imaging was compared to 2 CBCT units and a Multi-slice CT unit's radiation dose.	The effective dose (E) for NewTom 900 was 56.2 $\mu$ Sv; for the i-cat, it was 61.1 $\mu$ Sv; for the panoramic and lateral cephalograms, it was 10.4 $\mu$ Sv; for the multi slice ct, it was 429.7 $\mu$ Sv.
CBCT: cone beam computed tomography; 3D: three dimensional; 3D-CT: three dimensional computed tomography; 2D: two dimensional			

landmarks commonly used in orthodontic analysis on a human skull using two CBCT systems and concluded that the measurements from both CBCT systems were comparable to the gold standard direct skull measurements. Berco et al. (24) assessed the accuracy and reliability of 3D craniofacial measurements of CBCT scans. Seventeen landmarks were identified on a dry human skull using a 0.5 mm diameter stainless steel ball bearing. Linear measurements of 29 locations were made with digital calipers. It was concluded that CBCT was clinically accurate and made reliable 3D linear measurements of the craniofacial complex. They also concluded that the orientation of the skull at the time of the scanning does not affect the accuracy or reliability of the landmark measurements. Flores-Mir et al. (25) compared tooth length measurements from conventional panoramic radiographs and CBCT reconstructions to those taken with a digital caliper. Forty-eight extracted teeth were measured with digital calipers, and the radiographs were scanned and measured in Dolphin 3D. Conventional panoramic radiographs were relatively inaccurate, overestimating the lengths by 29%, and the CBCT panoramic reconstructions undervalued the lengths by 4%. Based on the review of the well conducted studies, there is evidence that the linear accuracy of the measurements from CBCT scans is comparable to physical measurements.

### Craniofacial Anatomy

King et al. (14) evaluated the vertical bone volume in the para-median palate (PP) of 183 adolescent patients (10-19 years) as a potential site for orthodontic implant placement. They suggested placing the implant at a distance of 4 mm distal and 3 mm lateral to the incisive foramen. The authors concluded that CBCT provided accurate assessments of the entire bone volume in the potential implant sites. De Rezende Barbosa et al. (26) conducted a study using CBCT to compare bone heights at sites of the hard palate. Through the use of CBCT, it was concluded that the paramedian sites 3 mm and 6 mm bilateral from the palatal suture are comparable in height to the site in the hard palate in the region of the maxillary first premolars. These findings can help to choose an alternate palatal implant site, suggesting a paramedian region. A review of CBCT's applications in this area shows

that CBCT can provide adequate information for evaluating the anatomy of the craniofacial region for surgical interventions.

### Craniofacial Malformations

Hamad et al. (27) demonstrated the clinical applicability of limited CBCT for the assessment of bone-grafted alveolar cleft. Seventeen bone bridges were examined using CBCT after alveolar bone grafting in 13 patients with cleft lip and palate. The results indicated that CBCT is beneficial for clinical evaluation of alveolar bone grafting before and after installation of dental implants or orthodontic treatment of the cleft-adjacent teeth. Oberoi et al. (28) used CBCT to evaluate the radiographic outcome of secondary alveolar bone grafting in individuals with nonsyndromic cleft lip and palate. Seventeen unilateral and 4 bilateral cleft lip and palate individuals had preoperative and postoperative CBCT scans that were analyzed. It was concluded that the secondary alveolar bone grafting of the cleft defect was successful. A review of CBCT's applications for evaluating craniofacial malformations show that CBCT can reliably depict craniofacial malformations primarily related to the osseous structures of the facial skeleton.

### Impactions

Walker et al. (29) examined the spatial relationship of impacted canines (n=27) using CBCT. They concluded CBCT images can show the presence or absence of canines, follicle size, inclination of the long axis, relative buccal and palatal positions, bony coverage over the tooth, adjacent structures, and dental development. They also concluded that 3D imaging is valuable in cases with impacted canines and improves the diagnosis and orthodontic treatment planning. Localization of maxillary impacted canines and their effects on incisor root resorption were examined using CBCT (n=200) by Liu et al. (4). They concluded that there is variation in maxillary canine impactions, and the resorption of incisors is a common feature. Algerban et al. (30) evaluated CBCTs of patients with unilaterally impacted canines. Statistically significant differences were found between the impacted and non-impacted canines. It was concluded that the use of CBCT to predict canine impaction was exceptional. Evaluation of the literature pertaining to impacted teeth in adolescent/or-

thodontic population shows that 3D evaluations of impacted teeth and their location are well demonstrated by CBCT.

### Maxillary Expansion

Rungcharassaeng et al. (31) evaluated 30 patients who required rapid maxillary expansion (RME) using CBCT in 2007. There was no significant difference in the dental expansion among the first premolar (P1), second premolar (P2), and first molar (M1). Age, appliance expansion, initial buccal bone thickness, and differential expansion showed a statistically significant co-relationship to the buccal bone thickness and dental tipping. However, the rate of expansion and retention time had no significant association. Garrett et al. (32) quantified the amount of skeletal expansion, alveolar tipping of the maxilla at the maxillary canine (C1), first maxillary premolar (P1), second maxillary premolar (P2), and maxillary first molar (M1) after rapid maxillary expansion (RME) using CBCT. Measurements were taken before and after the expansion (Hyrax appliance) protocol (n=30). The study showed that the skeletal expansion had a triangular pattern, i.e., more expansion in the anterior than in the posterior region. Woller et al. (33) evaluated the effects of rapid maxillary expansion on the maxillary complex in growing patients using CBCT. The CBCT scans of twenty-five rapid maxillary expansion patients were examined before treatment and after the last activation to evaluate the displacement at the circum-maxillary sutures. With the use of CBCT, it was determined that rapid maxillary expansion results in significant displacement of the bones of circum-maxillary sutures in growing patients. This section shows that CBCT can provide adequate information for planning maxillary expansion and similar interventional procedures.

### Mini-screw and Implant Studies

Gracco et al. (34) evaluated 72 patients between the ages of 20–44 years and studied the palatal bone thickness to determine the ideal location for implant placement using digital volumetric tomography. They concluded that the thickest bone was 4 mm behind and 6 mm lateral to the incisive foramen. Areas on the side of the median palatal suture appear to have adequate bone thickness for mini-screw placement. Kim et al. (35) evaluated surgical positioning of orthodontic mini-implants with guides on models using CBCT. The CBCT system was used to obtain virtual slices (0.1 to 0.15 mm) of the posterior maxilla. The authors concluded that the use of CBCT images as a guide for implant placement makes the procedure safer and can prevent inter-radicular damage compared to conventional guides (wire and resin guides) that depend more on the clinician's skill and experience. Hans-Joachim Nickenig et al. (17) assessed the reliability of implant placement after virtual planning of the implant positions using CBCT data and surgical guide templates. In all cases, the essential anatomical structures were protected, and no complications were detected in the postoperative panoramic radiographs. In 58.1% (147) of the 250 implants, a flapless surgery plan was realized. The results concluded that after virtual planning for the implants using CBCT data, the use of surgical templates to aid in implant placement is reliable for preoperative assessment of the implant size, position, and anatomical complications. This is also indicative in cases of flapless surgery. Landin et al. (36) compared the outcome of mini-implant placement us-

ing four different methods: blind placement, a single periapical radiograph, a single panoramic radiograph, and a small volume CBCT. It was shown that the common methods of blind placement or periapical radiographs resulted in a 50% and 60% occurrence (respectively) of root perforation. It was concluded that 3D imaging using CBCT was superior for preventing root perforation during surgical placement, with only a 5% occurrence of perforation. CBCT can provide reliable information for the planning and placement of mini-implants.

### Radiation Dose

Silva et al. (19) compared the doses for digital panoramic and cephalometric images from a Sirona DS Plus unit with the doses for 2 CBCT devices, the i-CAT and the NewTom DVT 9000, and a multi-slice CT, the Somatom Sensation. The equivalent and effective doses were calculated based on the International Commission on Radiological Protection's (ICRP) 2005 recommendations. The panoramic and lateral cephalometric imaging produced the lowest organ dose (13.1Sv), which was received by the thyroid gland. The multi-slice CT produced the highest mean organ dose (15,837.2Sv), which was received by the neck skin. The effective dose was also lowest for the panoramic and lateral cephalometric device (10.4Sv) and highest for the multi-slice CT (429.7Sv). The study concluded that digital images still deliver the lowest doses to patients, but when 3D is required in orthodontic practice, a CBCT should be preferred over a medical-CT image. The authors concluded that further studies are necessary to justify the routine use of CBCT in routine orthodontic treatment planning. Pauwels et al. (37) investigated the absorbed dose and effective dose for a large range of CBCT scanners. Measurements were performed on 14 CBCT devices. The results showed that for large FOV protocols, the effective dose ranged between 68 and 368 $\mu$ Sv, with the highest absorbed dose in the salivary glands. For medium FOV protocols, the effective dose ranged between 28 and 265 $\mu$ Sv and demonstrated a similar organ dose distribution. For the small FOV protocol, the effective dose ranged between 19 and 44 $\mu$ Sv. The average doses for large, medium, and small FOVs were 131, 88, and 34 $\mu$ Sv, respectively, showing the largest variability for large and medium FOVs. Radiation doses from CBCT scans depend on several factors, including the machine type, field of view, and age of the patient. This is significantly lower than the traditional multi-slice CT scanners but higher than any dental 2D acquisition.

### CONCLUSION

This review shows that there is evidence in the literature that CBCT does provide improved visualization of dento-facial structures, especially for the evaluation of syndromic patients and mini-implant sites. There is adequate evidence that CBCT is a lower dose alternative for orthognathic surgeries and is reliable from both a diagnostic and surgical perspective because of the measurement linear accuracy and ability to depict maxillofacial structures. The radiation dose of CBCT is significantly lower than medical-CT. It is challenging to make a fair comparison of the radiation doses with 2D imaging, but they are higher and dependent on the field of view and exposure parameters as well as age and tissue exposed.



**Peer-review:** Externally peer-reviewed.

**Author contributions:** Concept - A.T., A.M., S.Y., P.M.; Design - A.T., A.M., S.Y., P.M.; Supervision - A.T., S.Y., P.M.; Data Collection and/or Processing - A.T., A.M., S.Y., P.M.; Analysis and/or Interpretation - A.T., S.Y., P.M.; Literature Search - A.T., P.M.; Writing - A.T., A.M., S.Y., P.M.; Critical Reviews - A.T., A.M.

**Conflict of Interest:** No conflict of interest was declared by the authors.

**Financial Disclosure:** The authors declared that this study has received no financial support.

## REFERENCES

1. Van Elslande DC, Russett SJ, Major PW, Flores-Mir C. Mandibular asymmetry diagnosis with panoramic imaging. *Am J Orthod Dentofacial Orthop* 2008; 134: 183-92. [\[CrossRef\]](#)
2. Honda K, Natsumi Y, Sakurai K, Ishikura R, Urade M. Mucinous adenocarcinoma of the temporal region initially diagnosed as temporomandibular disorders: a case report. *J Oral Pathol Med* 2006; 35: 582-5. [\[CrossRef\]](#)
3. Tsiklakis K, Syriopoulos K, Stamatakis HC. Radiographic examination of the temporomandibular joint using cone beam computed tomography. *Dentomaxillofac Radiol* 2004; 33: 196-201. [\[CrossRef\]](#)
4. Liu DG, Zhang WL, Zhang ZY, Wu YT, Ma XC. Localization of impacted maxillary canines and observation of adjacent incisor resorption with cone-beam computed tomography. *Oral Surg Oral Med Oral Pathol Oral Radiol Endod* 2008; 105: 91-8. [\[CrossRef\]](#)
5. Aboudara CA, Hatcher D, Nielsen IL, Miller A. A three-dimensional evaluation of the upper airway in adolescents. *Orthod Craniofac Res* 2003; 6 (Suppl 1): 173-5. [\[CrossRef\]](#)
6. Maverna R, Gracco A. Different diagnostic tools for the localization of impacted maxillary canines: clinical considerations. *Prog Orthod* 2007; 8: 28-44.
7. Mozzo P, Procacci C, Tacconi A, Martini PT, Andreis IA. A new volumetric CT machine for dental imaging based on the cone-beam technique: preliminary results. *Eur Radiol* 1998; 8: 1558-64. [\[CrossRef\]](#)
8. Yamamoto K, Ueno K, Seo K, Shinohara D. Development of dental-maxillofacial cone beam X-ray computed tomography system. *Orthod Craniofac Res* 2003; 6 (Suppl 1): 160-2. [\[CrossRef\]](#)
9. da Silva Filho OG, Montes LA, Torelly LF. Rapid maxillary expansion in the deciduous and mixed dentition evaluated through posteroanterior cephalometric analysis. *Am J Orthod Dentofacial Orthop*
10. Sandikcioglu M, Hazar S. Skeletal and dental changes after maxillary expansion in the mixed dentition. *Am J Orthod Dentofacial Orthop* 1997; 111: 321-7. [\[CrossRef\]](#)
11. Korbmacher H, Kahl-Nieke B, Schöllchen M, Heiland M. Value of two cone-beam computed tomography systems from an orthodontic point of view. *J Orofac Orthop* 2007; 68: 278-89. [\[CrossRef\]](#)
12. Hoffmann J, Westendorff C, Schneider M, Reinert S. Accuracy assessment of image-guided implant surgery: an experimental study. *Int J Oral Maxillofac Implants* 2005; 20: 382-6.
13. Siessegger M, Schneider BT, Mischkowski RA, Lazar F, Krug B, Klesper B, et al. Use of an image-guided navigation system in dental implant surgery in anatomically complex operation sites. *J Craniomaxillofac Surg* 2001; 29: 276-81. [\[CrossRef\]](#)
14. King KS, Lam EW, Faulkner MG, Heo G, Major PW. Vertical bone volume in the paramedian palate of adolescents: a computed tomography study. *Am J Orthod Dentofacial Orthop* 2007; 132: 783-8. [\[CrossRef\]](#)
15. Kuroda S, Sakai Y, Tamamura N, Deguchi T, Takano-Yamamoto T. Treatment of severe anterior open bite with skeletal anchorage in adults: comparison with orthognathic surgery outcomes. *Am J Orthod Dentofacial Orthop* 2007; 132: 599-605. [\[CrossRef\]](#)
16. Madrigal C, Ortega R, Meniz C, López-Quiles J. Study of available bone for interforaminal implant treatment using cone-beam computed tomography. *Med Oral Patol Oral Cir Bucal* 2008; 13: E307-12.
17. Nickenig HJ, Eitner S. Reliability of implant placement after virtual planning of implant positions using cone beam CT data and surgical (guide) templates. *J Craniomaxillofac Surg* 2007; 35: 207-11. [\[CrossRef\]](#)
18. Farman AG, Scarfe WC. Development of imaging selection criteria and procedures should precede cephalometric assessment with cone-beam computed tomography. *Am J Orthod Dentofacial Orthop* 2006; 130: 257-65. [\[CrossRef\]](#)
19. Silva MA, Wolf U, Heinicke F, Bumann A, Visser H, Hirsch E. Cone-beam computed tomography for routine orthodontic treatment planning: a radiation dose evaluation. *Am J Orthod Dentofacial Orthop* 2008; 133: 640.e1-5. [\[CrossRef\]](#)
20. Hechler SL. Cone-beam CT: applications in orthodontics. *Dent Clin North Am* 2008; 52: 809-23, vii. [\[CrossRef\]](#)
21. Holberg C, Steinhäuser S, Geis P, Rudzki-Janson I. Cone-beam computed tomography in orthodontics: benefits and limitations. *J Orofac Orthop* 2005; 66: 434-44. [\[CrossRef\]](#)
22. Periago DR, Scarfe WC, Moshiri M, Scheetz JP, Silveira AM, Farman AG. Linear accuracy and reliability of cone beam CT derived 3-dimensional images constructed using an orthodontic volumetric rendering program. *Angle Orthod* 2008; 78: 387-95. [\[CrossRef\]](#)
23. Stratemann SA, Huang JC, Maki K, Miller AJ, Hatcher DC. Comparison of cone beam computed tomography imaging with physical measures. *Dentomaxillofac Radiol* 2008; 37: 80-93. [\[CrossRef\]](#)
24. Berco M, Rigali Jr PH, Miner M, DeLuca S, Anderson NK, Will LA. Accuracy and reliability of linear cephalometric measurements from cone-beam computed tomography scans of a dry human skull. *Am J Orthod Dentofacial Orthop* 2009; 136: 17.e1-17.e9. [\[CrossRef\]](#)
25. Flores-Mir C, Rosenblatt MR, Major PW, Carey JP, Heo G. Measurement accuracy and reliability of tooth length on conventional and CBCT reconstructed panoramic radiographs. *Dental Press J Orthod* 2014; 19: 45-53. [\[CrossRef\]](#)
26. de Rezende Barbosa GL, Ramirez-Sotelo LR, Tavora DM, Almeida SM. Comparison of median and paramedian regions for planning palatal mini-implants: a study in vivo using cone beam computed tomography. *Int J Oral Maxillofac Surg* 2014; 43: 1265-8. [\[CrossRef\]](#)
27. Hamada Y, Kondoh T, Noguchi K, Iino M, Isono H, Ishii H, et al. Application of limited cone beam computed tomography to clinical assessment of alveolar bone grafting: a preliminary report. *Cleft Palate Craniofac J* 2005; 42: 128-37. [\[CrossRef\]](#)
28. Oberoi S, Chiqurupati R, Gill P, Hoffman WY, Vargervik K. Volumetric assessment of secondary alveolar bone grafting using cone beam computed tomography. *Cleft Palate Craniofac J* 2009; 46: 503-11. [\[CrossRef\]](#)
29. Walker L, Enciso R, Mah J. Three-dimensional localization of maxillary canines with cone-beam computed tomography. *Am J Orthod Dentofacial Orthop* 2005; 128: 418-23. [\[CrossRef\]](#)
30. Alqerban A, Jacobs R, Fieuws S, Willems G. Radiographic predictors for maxillary canine impaction. *Am J Orthod Dentofacial Orthop* 2014; 147: 345-54. [\[CrossRef\]](#)
31. Rungcharassaeng K, Caruso JM, Kan JY, Kim J, Taylor G. Factors affecting buccal bone changes of maxillary posterior teeth after rapid maxillary expansion. *Am J Orthod Dentofacial Orthop* 2007; 132: 428.e1-8. [\[CrossRef\]](#)
32. Garrett BJ, Caruso JM, Rungcharassaeng K, Farrage JR, Kim JS, Taylor GD. Skeletal effects to the maxilla after rapid maxillary expansion assessed with cone-beam computed tomography. *Am J Orthod Dentofacial Orthop* 2008; 134: 8-9. [\[CrossRef\]](#)
33. Woller JL, Kim KB, Behrents RG, Buschang PH. An assessment of the maxilla after rapid maxillary expansion using cone beam computed tomography in growing children. *Dental Press J Orthod* 2014; 19: 26-35. [\[CrossRef\]](#)

34. Gracco A, Lombardo L, Cozzani M, Siciliani G. Quantitative cone-beam computed tomography evaluation of palatal bone thickness for orthodontic miniscrew placement. *Am J Orthod Dentofacial Orthop* 2008; 134: 361-9. [\[CrossRef\]](#)
35. Kim SH, Choi YS, Hwang EH, Chung KR, Kook YA, Nelson G. Surgical positioning of orthodontic mini-implants with guides fabricated on models replicated with cone-beam computed tomography. *Am J Orthod Dentofacial Orthop* 2007; 131: S82-9. [\[CrossRef\]](#)
36. Landin M, Jadhav A, Yadav S, Tadinada A. A comparative study between currently used methods and Small Volume- Cone Beam Tomography for surgical placement of mini implants. *Angle Orthod* 2015; 85: 446-53. [\[CrossRef\]](#)
37. Pauwels R, Beinsberger J, Collaert B, Theodorakou C, Rogers J, Walker A, et al. Effective dose range for dental cone beam computed tomography scanners. *Eur J Radiol* 2012; 81: 267-71. [\[CrossRef\]](#)