



Review

# Up-to-Date Approach in the Treatment of Impacted Mandibular Molars: A Literature Review

İpek Tamer , Evren Öztaş , Gülnaz Marşan 

Department of Orthodontics, İstanbul University İstanbul School of Dentistry, İstanbul, Turkey

Cite this article as: Tamer İ, Öztaş E, Marşan G. Up-to-Date Approach in the Treatment of Impacted Mandibular Molars: A Literature Review. Turk J Orthod 2020; 33(3): 183-91.

## ABSTRACT

Eruption problems in the mandibular molars are rare, but they have to be diagnosed and treated early. Treatment of impacted molars is challenging due to a limited access and complexity of the mechanics that needs to be applied. Methods for managing impacted or tilted mandibular molars include orthodontic repositioning, surgical uprighting, and extraction with or without transplantation of the third molar into the extraction site.

This review highlights the methods and clinical procedures of surgical and orthodontic uprighting procedures of mandibular molars with different degrees and levels of impaction. It further discusses the use of the ramus screw as a temporary anchorage device in the uprighting of horizontally impacted mandibular molars.

**Keywords:** Impacted teeth, mandibular, molar uprighting, orthodontics, ramus screws

## INTRODUCTION

Impaction of permanent teeth is a complex problem, refractory to routine orthodontic treatment, and it must be managed effectively. Relative incidence of impaction is the highest for maxillary and mandibular third molars, followed by maxillary canines and lower second molars (1). Second-molar impaction is a very rare condition occurring prevalently in the mandible, and its prevalence ranges between 0.06% and 0.3% of the population, but a higher ratio has been reported in orthodontic patients (2%-3%) (1, 2). Although the consequences are rare, there are many functional, periodontal, hygienic, and prosthodontic reasons justifying the need for treatment of impacted mandibular molars.

### Aetiology of Molar Impaction

The major etiologic factor in second-molar impaction is the lack of space. The space required for the eruption of second molars is provided via the apposition and resorption procedures. Any interruption during these procedures results in eruption problems of molars (3). An inadequate mesial movement of first molars due to ankylosed deciduous molars or early loss of primary molars may lead to eruption disturbances of molars (4). Other local factors in second-molar impactions are the ectopic position, obstacles in the path of eruption, such as an odontogenic tumor or cyst, and morphologic anomalies such as root invaginations or deflections (5, 6). Systemic factors such as syndromes related to multiple tooth impactions and mutations of the PTH 1 receptor may also contribute the eruption failure of molars. If the impaction is bilateral and involves both arches, a systemic or genetic etiology is likely (7).

Iatrogenic factors also play an important role primarily in second-molar impactions. An incorrectly fitted band cemented on the first mandibular molar may give rise to eruption problems in second molars (8). In addition, the orthodontist may inadvertently impact a second molar while attempting to increase the mandibular length with a lip bumper or the Arnold appliance (9, 10).

### Diagnosis of Impacted Lower Mandibular Molars and the Need for Treatment

Impacted second lower molars are typically diagnosed between 11 and 14 years of age, and they are rarely the seldom concern for orthodontic referral. Being an asymptomatic pathology, they are generally diagnosed as a secondary finding during an orthodontic examination (11).

The absence of one molar while the contralateral is normally erupted should alert the orthodontist for molar impaction, and eruption of the molar should be evaluated by orthopantomographic radiography.

In a panoramic evaluation of a preadolescent, if a lower third-molar follicle is positioned on top of the developing second-molar crown, this situation is also an early warning of a future impaction (Figure 1) (12).

As an impacted lower second molar is diagnosed, the treatment option should be either uprighting via orthodontic or surgical procedures, extraction of the impacted tooth and restoring the space via prosthodontic solutions, or orthodontic third-molar mesialization. To the best of our knowledge, there is no literature supporting the extraction of a healthy impacted tooth in the favor of placing an implant. Uprighting impacted molars also prevent the possible neurologic injury, which could be caused by closed proximity to inferior alveolar nerve. Uprighting the tooth primary to extraction facilitates the surgical procedure and precludes potential injuries to the roots of adjacent molars (6).

Untreated impacted lower molars bring about the risks of periodontal problems, tooth decay, and external root resorption in the adjacent molar roots (8). Literature proves that mesially impacted lower molars accentuate the periodontal bone loss, which increases the risk of pericoronitis and immigration of inflammatory cells by causing supra- and subgingival plaque accumulation, thus badly affecting the bone level of adjacent molar (13). Uprighting of inclined molars decreases the pocket depth by 0.1 mm on each tooth surface, facilitating the plaque control (14).

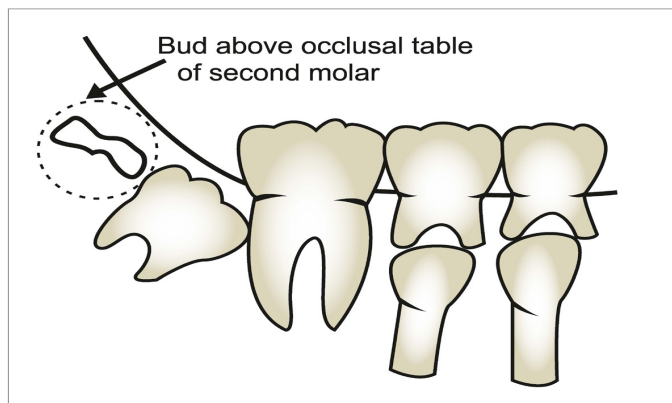


Figure 1. Lower third molar follicle positioned on top of the second molar, an early sign of second molar impaction

From Kravitz et al. (2016). Kravitz ND, Yanosky M, Cope JB, Silloway K, Favagehi M. Surgical Uprighting of Lower Second Molars. *J Clin Orthod*. 2016;50:33-40.

Besides the periodontal advantages, uprighting molars allows the parallel placement of dental implants, idealizing the prosthodontic rehabilitations; hence, occlusal forces are equally distributed, and the resistance of teeth to masticatory forces increase. Uprighting of inclined molars also eliminates primary contacts, thus preventing traumatic occlusion and TMJ problems (15). Uprighting of lower molars plays an important role in the establishment of vertical dimension.

### Treatment of Inclined or Impacted Molars

#### Classification of Impacted Molars

Classifying the degree of impaction determines the level of complexity of the problem and facilitates the decision making in the favor of extracting or uprighting. The relative position of molar impaction is assessed using the Pell–Gregory and Winters Classifications (16, 17).

Winters (16) classified impacted molars according to their angulations, being vertical, horizontal, distoangular, mesioangular, buccoangular, or linguoangular. The classification by Pell–Gregory (17) is a two-phased classification and categorizes both the depth of the impaction and its relationship with the mandibular ramus. In this classification, the depth of impaction ranges between Classes A, B, and C, from superficial to deep (Figure 2).

When making a decision on the uprightability of an impacted molar, especially in horizontal impactions, the depth of impaction should be the primary concern. According to this classification, Position B is the best candidate for uprighting, whereas Position A, although the most superficial, is the worst. Uprighting a molar that is horizontally and superficially impacted may result in occlusal traumas.

Position C, being the deepest, is the most favorable for uprighting mechanics; however, conventional orthodontics is insufficient, and the ramus bone screw anchorage is needed (18). When an impacted molar is encountered, position B is the easiest to upright even with conventional mechanics, however with the improvements like ramus screws position C, although more difficult, is still uprightable.

#### Treatment Options for Impacted Molars

Extraction or uprighting of an impacted molar is the most critical decision in the treatment planning. Factors affecting this decision are the degree of impaction, the relationship of the tooth with the critical anatomic structures (inferior alveolar nerve, lingual artery), caries, root dilacerations, and periodontal problems. The complexity of the surgical procedure in the case of extraction should also be considered (19).

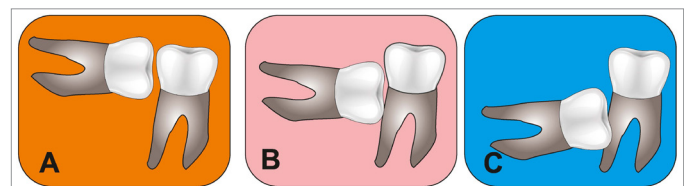


Figure 2. Pell-Gregory classification

Extraction is an alternative for impacted molars, which appears to have no chance of uprighting; in this case, if the second molar is extracted, the third molar may be allowed to erupt in the second molar position (20). However, if there is a time lapse between the extraction of the second molar and the eruption of the third molar, the third molar may not take the position of the second molar, and it may still stay impacted or inclined (20). On the contrary, Orton and Gibbs' study states that none of the third molars is impacted due to the extraction of an impacted second molar (21). Even so, each case should be evaluated carefully and individually. Extraction of an impacted molar followed by a prosthodontic rehabilitation is another utilizable alternative. However, to the best of our knowledge, no literature supports the placement of an implant in the place of an impacted molar that can successfully be uprighted via orthodontic and surgical procedures.

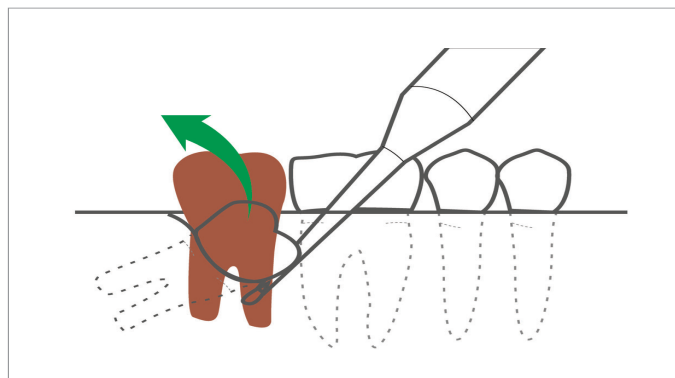
A healthy tooth has a chance to serve a lifetime, whereas implants lead to various risks of failure due to periimplantitis, either patient or doctor related (22). Therefore, if impacted molars can be uprighted either surgically or orthodontically, they definitely should.

There are orthodontic and surgical treatment options for this difficult problem. Surgical alternatives range from simply uncovering the tooth to repositioning and uprighting it surgically.

### Surgical Uprighting of Impacted Molars

Surgical uprighting is a fast and effective treatment alternative in cases where orthodontic treatment is contraindicated, patient cooperation is inadequate, or the molar is submerged deep below the soft tissue. This method is a safe and efficient solution with minimal tooth morbidity and a good long-term prognosis (12).

Although surgical uprighting is most commonly applied in mesially impacted lower second molars, it is also applicable in other impacted teeth that have a limited access or that did not respond to conventional orthodontic methods (12). A surgical uprighting procedure is generally applied by an oral surgeon and defined as luxation of an impacted tooth within its socket using a straight elevator (Figure 3).



**Figure 3.** Illustration of surgical uprighting procedure

From Kravitz et al. (2016). Kravitz ND, Yanosky M, Cope JB, Silloway K, Favagehi M. Surgical Uprighting of Lower Second Molars. *J Clin Orthod.* 2016;50:33-40.

Prior to luxation, a minimal amount of bone is removed around the crown, ensuring that the cementomenamel junction and root surfaces are covered with bone. The tooth is tipped distally and superiorly until the occlusal surface is approximately level with the occlusal plane. The difference between this method and autotransplantation or transalveolar transplantation is that this technique is applied only within the tooth socket (12).

Since the tooth is not removed from its socket, the apical vessels remain intact, and saliva contamination of the roots is prevented; thus, it has a better long-term prognosis compared to autotransplantation (23).

### Surgical Technique

Prior to the surgical procedure, lower brackets are bonded until the first molars, and leveling should be completed.

Surgery is performed under local anesthesia. A full thickness flap is extended, and the adjacent third molar should be removed to facilitate the uprighting of the second molar. Research indicates that the third molar is only to be extracted if it hinders the uprighting of the second molar. The third molar acts as a support for the previously impacted molar, and it contributes to the primary stability. Also, if the uprighted molar is extracted for any reason after the surgical uprighting, the third molar may be used in its position (23).

Prior to uprighting, an electric handpiece is used to remove the bone around the crown. A straight elevator is then placed mesially to the second molar, and in a slow and controlled manner, the tooth is tipped superiorly and distally, bringing it to its ideal position. The second molar is bonded immediately following the luxation, and the leveling procedures are continued on nickel-titanium (Niti) archwires.

### Orthodontic Procedure

The first orthodontic appointment is scheduled 7–14 days following the surgery. A 0.014 or 0.018 NiTi is then applied for stabilization and improved alignment. Routine orthodontic appointments are scheduled every 6–8 weeks afterwards. Panoramic radiographs should be taken to assess bone health, and tooth vitality should be controlled (12). Bone formation should be seen in the mesial and distal parts of the impacted tooth after 9–10 months. Fixed appliances could be removed after the bone formation. Due to the previous position of the tooth, an acutely angled osseous defect is seen on the mesial side. It regenerates after the uprighting, but in the case of periodontitis, healthy periodontal attachment is not observed. In this case, surgical uprighting may worsen the present defect. Thus, surgical uprighting is contraindicated in periodontitis cases (24).

### Risks and Complications of Surgical Uprighting

The primary risks of surgical uprighting are pulpal necrosis, external root resorption, and ankylosis. Although periodontal healing complications and the need for root canal treatment for the uprighted tooth are rare, an advanced age, completed root formation, and excessive inclination may cause an irreversible strain in the apical vessels and result in negative prognosis (25).

In the retrospective cohort study of Padwa et al. (25), radiographic outcomes of surgical uprighting are assessed. According to the study results, surgical uprighting is successful in all the cases, and they stay healthy in the 1-year follow-up period.

### Orthodontic Treatment of Impacted Molars

The best timing for treating impacted first and second molars is between 11 and 14 years of age, when the root formation is still not completed. The type of treatment depends on the tilt of the tooth, the degree of impaction, and the amount of orthodontic tooth movement needed (26).

When choosing the treatment mechanics, required tooth movements should be evaluated in three spatial planes (26). Molar uprighting should be the result of an appropriate combination of sagittal and vertical tooth movements.

Minor malpositions on second molars can be corrected by positioning an elastic separator in between two teeth, while more severe malpositioning demands the use of surgical methods or orthodontically assisted eruption techniques (27).

Orthodontically assisted eruption is one of the most efficient treatment options for impacted mandibular molars. This procedure can be done with or without surgically uncovering the

impacted tooth. The general approach is to bond an attachment on the buccal or distobuccal surface of the impacted tooth, followed by the application of an uprighting force. The uprighting force can be delivered by simple tip back cantilever bends, a Niti coil spring, a superelastic Niti archwire, or various uprighting springs and segmental mechanics (26).

Apart from these methods, various types of uprighting springs, such as Australian uprighting spring, cantilever spring, Sander spring, helical uprighting spring, or push spring, can be utilized (15).

### Uprighting Mandibular Molars Using Simple Cantilever Mechanics

The 0.017\*0.025 TMA archwire is used in all types of cantilever bends for molar uprighting due to its ability to deliver a lighter, continuous force and higher springness compared to stainless steel wires. Since cantilever uprighting springs are used as an auxiliary archwire, the main archwire should always be a full-dimensional stainless steel wire. A 0.019\*0.025 inch wire is recommended when working with the 0.022-slot dimension, while a 0.017\*0.025 inch wire is suitable when using brackets with the 0.018-slot dimension. Cantilever springs generate tooth movement in three spatial planes: distal crown tipping in the mesiodistal direction, and extrusion in the vertical plane (26). They generate a force, but most importantly a moment to tip the molar to its correct position. The length of the cantilever determines the moment-force ratio. A shorter cantilever causes a greater extrusion force compared to a longer one (27).

All simple cantilever mechanics generate an extrusive force as the inclination of the molar is corrected, frequently necessitating occlusal adjustments during the treatment. Extrusion is an inevitable side effect of cantilever mechanics, but it does not cause serious problems in the majority of cases (28). Molar extrusion is a desired side effect if the tooth is below the functional occlusal plane, for example when the molar has been impacted following sagittal expansion or lip bumper therapy (26).

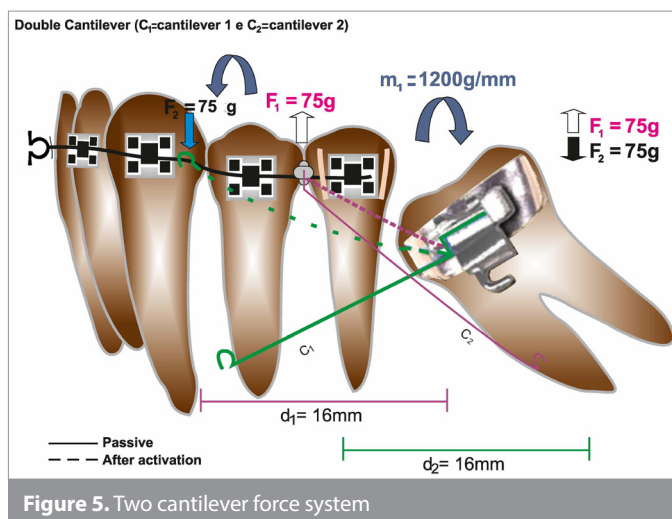
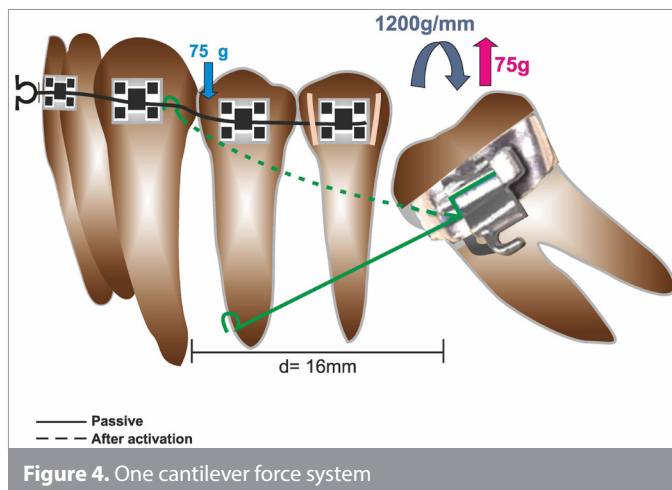
In such cases, simple tip back mechanics can be used; however, if the tipped molar is above the functional occlusal plane, intrusion of the molar will be needed, requiring more complex mechanics (28).

Two different force systems are used in the Cantilever mechanics:

1. One Cantilever Force System (Figure 4)
2. Two Cantilever Force System (Figure 5)

The one cantilever force system is a simplified way to apply a segmented arch technique. In this type of cantilever, a moment to tip the molar into its correct position is generated, and along with its activation, a vertical force is generated causing the molar to erupt vertically (29). To prevent this extrusive moment, a counteracting intrusive force is required (Figure 4).

In 1992, Weiland et al. (15) reported that the extrusive force caused by the cantilever can be cancelled by a second cantile-





ver. A second cantilever is placed between the bicuspid, and the loose end is attached to a piece of SS wire in the molar band, acting as an opposite force creator to the first cantilever (Figure 5). The two cantilever system is designed to overcome the side effects of uprighting cantilever springs on premolars: while the first cantilever produces extrusion of the molar, second cantilever neutralizes this effect.

When both springs are activated equally, vertical forces will cancel each other, and no extrusive force will be seen on the tipped molar (15, 29).

Besides, the mechanical advantages of applying two cantilevers may cause soft tissue irritations and thus be an uncomfortable option for the patient. The Sander spring, being a more comfortable and neater alternative, may be used instead (26).

In patients with a strong muscle pattern, occlusal forces are found to be effective in the prevention of extrusion; however, in patients with a weak muscular activity, extrusion should be prevented with additional mechanics (30). Since cantilever mechanics use the archwire as an anchorage unit, the unwanted side effects on the anchorage unit can be eliminated using skeletal anchorage. For patients treated with one or two cantilever mechanics, interdental mini implants can also be used to prevent the undesired side effects (31).

#### Skeletal Anchorage in the Treatment of Impacted Molars

Uprighting molars require a great amount of anchorage control. Ankylosed teeth, dental implants, and mini implants are useful in providing the absolute anchorage for uprighting and avoiding

undesired tooth movements (10). Since this kind of anchorage control is not possible in conventional molar uprighting methods, reciprocal tooth movements in anchorage units and undesired extrusion of teeth may be encountered, resulting in a prolonged treatment time (32).

With the development of skeletal anchorage, more precise force systems can be applied on target tooth, resulting in more efficient tooth movements in a shorter period of time. Lee et al. (33) used sectional mini-implant supported mechanics to upright mandibular second molars. In this method, a mini implant is placed in the mesial or distal side of the impacted tooth.

The retromolar area is frequently used as an anchorage point on the distal side of impaction. Using the retromolar area to position orthodontic implants was first proposed by Roberts et al. (34) in 1990, and using it in the method for mandibular molar uprighting was later proposed by Shellart et al. (35) in 1996. In this method, the molar is uprighted via a distalizing force, exerted through the use of elastomeric threads. The uprighting procedure generally requires a low force of 50–80 gr. The tooth is uprighted as a result of distally directed “pulling” force (33) (Figure 6a).

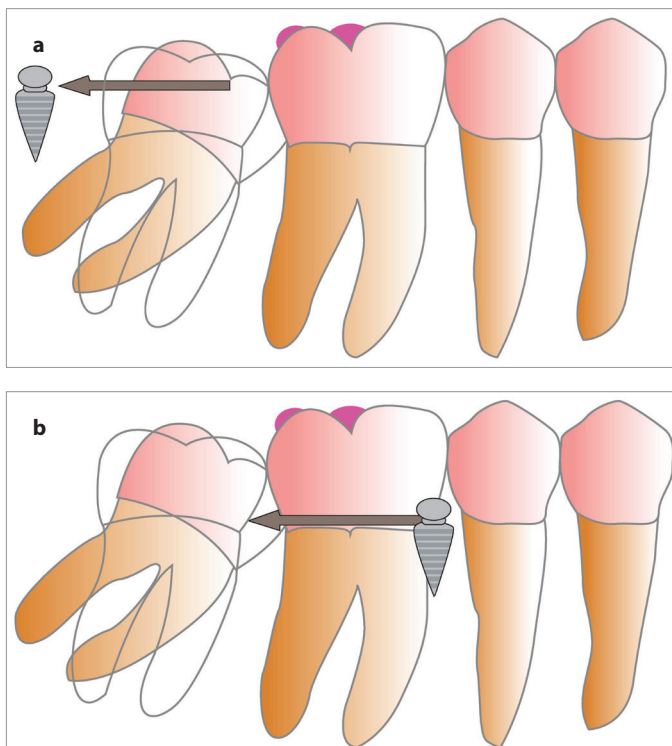
The retromolar area is a suitable anatomic place to position mini implants because of the compact bone that contributes the primary stability. However, the thick overlying soft tissue and poor accessibility may hinder the miniscrew insertion. The position of the mandibular canal should also be carefully examined to prevent any neurologic complications upon screw insertion (36).

In an adolescent patient with a developing third molar, it is difficult to insert a miniscrew in the retromolar area unless the third molar is extracted. In such cases, the miniscrew can be inserted on the mesial side of the tipped molar to generate a “pushing” force (Figure 6b). On the mesial side, the miniscrew is generally inserted in between the roots of the second premolar and the first molar.

The appliance design should be made according to the specific needs of the case, such as the screw insertion site, and the force system required for uprighting. When the screw is inserted on the mesial side, the “pushing” force is exerted via an open coil spring. Miniscrews used for anchorage are typically titanium mini implants 1.8 mm in diameter and 7 mm long. The average treatment time for molar uprighting using miniscrews is reported to be 7 to 9 months (33, 36).

In the sectional-miniscrew-assisted molar uprighting method developed by Lee et al. (33), a molar tube is bonded on the molar to be uprighted. In this method, either the buccal surface of the teeth should be accessible in the mouth or the tooth should be surgically uncovered. Nienkemper et al. (37) developed an alternative method suitable for cases in which only the distal cusp of the teeth is accessible. This method avoids the need for surgical exposure of the buccal surface.

Mini implants are positioned in the inter radicular area between second premolar and the first molar. A buccal tube is then bond-



**Figure 6. a, b.** Molar uprighting as a result of distally directed pulling force (a). Molar uprighting as a result of pushing force (b)

ed on the distal cusp of the impacted molar, and the slot is rotated 90 degrees so that it lies buccolingually (Figure 7. a, b). 0.018 SS archwire is bent vertically from the tube to the level of the implant, parallel to the occlusal plane, ending with a loop mesial to the mini implant. A Niti spring is then placed between the loop and mini implant to exert the pushing and uprighting necessary force (37).

In this type of treatment approach, only lateral forces are delivered to the mini implant, whereas in the previously discussed methods, axial forces are exerted on the miniscrew. It is known that axial loading is an important factor in miniscrew failure; thus, these mechanics are advantageous compared to other mini-implant-assisted uprighting mechanics (37).

### Ramus Screws in Uprighting Mandibular Impacted Molars

Horizontally impacted molars are complex problems that are refractory to routine orthodontic treatment methods. An efficient treatment strategy requires the development of a strong anchorage device from extra-alveolar sites (38, 39). Roberts et al. (40) utilized osseointegrated implants as extra-alveolar temporary anchorage devices in 1990 to close edentulous spaces in the mandibular arch. Although these implants are effective and reliable, they are not effective in uprighting horizontally impacted mandibular second molars because there is no convenient space to place the osseointegrated fixture distal to the impaction site (41).

Other researchers introduced the use of titanium miniscrews in the interradicular area; however, they are not well suited for complex problems such as horizontal impaction, and they have higher failure rates, particularly in the posterior mandible (30, 42). Interradicular mini implants also are not suitable for deeply impacted molars since they cause limitations such as root dam-

age, movement within the bone, and interference with the path of tooth movement (42).

Realizing the limitations of conventional temporary anchorage devices, Chang et al. (39) expanded the skeletal anchorage concept by developing a stainless steel bone screw, 2 mm in diameter, that is suitable for extra-alveolar sites, such as the mandibular buccal shelf (MBS), zygomatic process, and mandibular ramus.

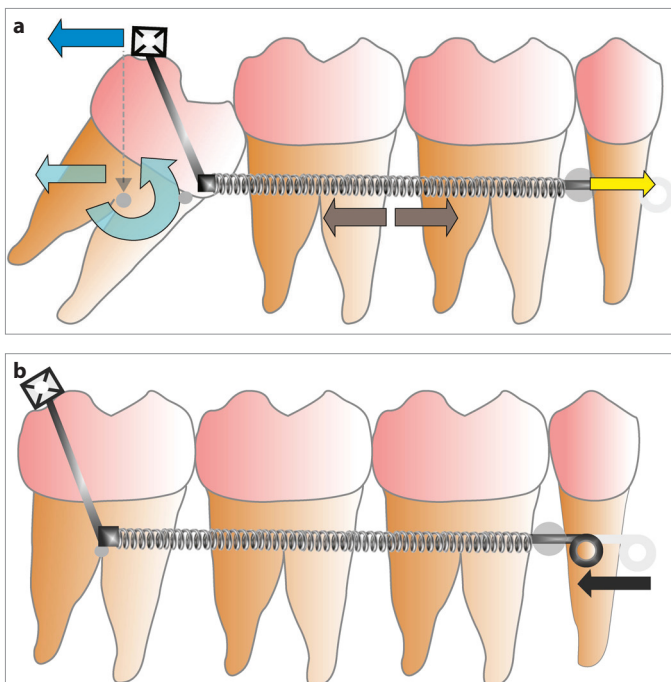
The MBS bone screws are placed laterally to the first and second molars; thus, they do not interfere with the retromolar region of impaction. However, mechanics to upright horizontally impacted molars using MBS screws are complicated and difficult to control. To be able to upright a horizontally impacted molar, bone screws are placed in the ramus of the mandible to provide a more superior and posterior direction of traction. Ramus of the mandible is a suitable place to place miniscrews owing to a thick cortical bone tissue.

Ramus screw anchorage is utilized to upright deeply and horizontally impacted second molars, and it is also used in uprighting third molars that are closed to the mandibular canal, and prior to extraction to reduce the risk of paresthesia and surgery-related complications (39).

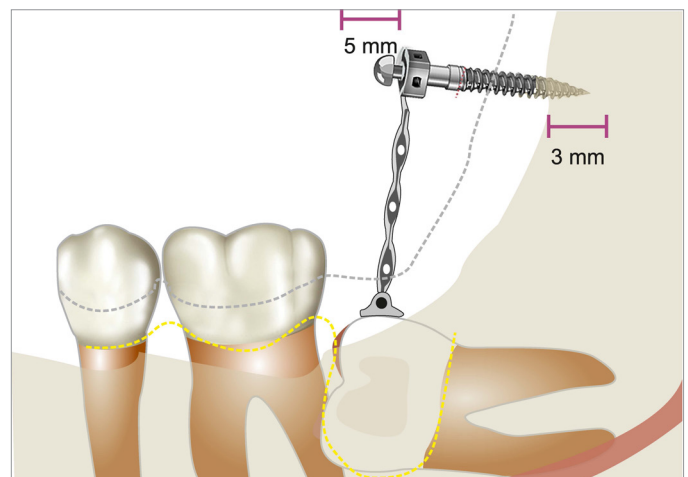
Ortho bone screws developed by Chang et al. (39) are used in the mandibular ramus area.

Extra-alveolar screws (2 mm\*12 mm) are suitable for the mandibular buccal shelf area; however, in the ramus area, a longer screw is needed because of the thick movable mucosa.

A ramus screw should penetrate a thick mucosa, as well as the inferior fibers of the temporalis muscle, and it also has to have an average of 3 mm of bone engagement. To facilitate the oral hygiene, the screw head should be about 5 mm above the soft tissue. To be able to provide the adequate bone penetration and to best fit the anatomical features of the anterior ramus region, a 2 mm\*14 mm screw is used in the mandibular ramus (6, 19, 39) (Figure 8).



**Figure 7. a, b.** An alternative Molar uprighting method, designed by Nienkemper et al.



**Figure 8.** Ramus screw length, and appropriate insertion depth

### Clinical Procedure

A full thickness flap is reflected exposing the clinical crown of the impacted molar, and bone is removed to uncover the tooth surface and establish a path of movement for uprighting. An attachment is bonded on the buccal surface of the impacted molar.

Ramus screws are installed under local anesthesia, without flap elevation or predrilling. To avoid the occlusal interferences, the optimal site to insert the screw is midway between the external and internal oblique ridges of ascending ramus, and about 5–8 mm above the occlusal plane (Figure 9). Ramus screws are loaded immediately after the insertion. Uprighting force is exerted via elastomeric chains (Power chain) stretched between the ramus screw and a button or eyelet bonded on the impacted teeth. Elastic chain is activated by one loop in every 4 weeks.

According to the study by Chang et al. (39) performed on 40 horizontally impacted molars uprighted with ramus screws, this method was found to be predictable and effective, and also, the average time for uprighting the molar was found to be maximum 4 months. At the 5<sup>th</sup> month, the previously impacted molars are bonded with a routine buccal tube.

Selecting bonding devices is as important as the screw insertion site in the molar uprighting procedures. The most popular bondable attachments for uprighting molars are buttons or eyelets. When choosing between these two options, the first concern is the line of force. Buttons are well designed for horizontal traction, but elastics can be more easily displaced as the direction of force has a vertical orientation. The second concern should be placing and replacing the chains, and an eyelet should be bonded with the elastic attached previously, whereas buttons are more convenient if the elastic must be changed. If the attachment is bonded on an erupted surface of the tooth and the line of traction is appropriate, buttons are convenient; however, if the attachment is bonded on an unerupted tooth surface, eyelets are safer. Also, the flat surfaces of an eyelet facilitate the manipulation when holding it with hemostat or pliers making it a more comfortable choice for impacted molars (21). Flowable

composite resin can be used to secure the elastic chain on each type of attachment to prevent the detachment of the elastic chain. (19)

### Potential Risks and Complications of Ramus Screws

For temporary anchorage devices in a challenging intraoral site such as the anterior ramus, the major concern are the complications and failure.

### Soft Tissue Hyperthrophy

Alveolar mucosa in the anterior region of the ramus is very thick and mobile, and it is also attached to an active muscle tissue. Thus, controlling soft tissue inflammation in this area can be a challenge. Complex surgical and mechanical procedures may compromise the periodontium in areas where it is difficult to maintain oral hygiene, so periodontal health should be monitored carefully in ramus screw cases prior to, during, and after the treatment (43).

The root form and divergence are also important considerations relative to periodontal prognosis. Divergence of roots is preferable in terms of periodontal prognosis after uprighting compared to fusion. This is an important factor when deciding on the extraction of molars.

### Damage to anatomical structures

The anatomical structure presenting the most serious risk for complication is the neurovascular bundle of the inferior alveolar canal. Under normal clinical conditions, the ramus screw is about 15–20 mm away from the neurovascular bundle, and post-operative panoramic radiographs indicate that the screw tip is about 5–8 mm away from the canal after the screw insertion. Thus, if the clinical instructions upon positioning the screw are followed carefully, the risk of damaging the neurovascular bundle is minimal, except for the anatomical variations (6).

### Screw Fracture or Failure

Fracture is an important risk for small-diameter screws made of a brittle material such as titanium, especially when inserted in the cortical bone (44). The risk of fracture is decreased by increasing the diameter or using a tougher material such as stainless steel. Predrilling also reduces the risk of fracture; however, because

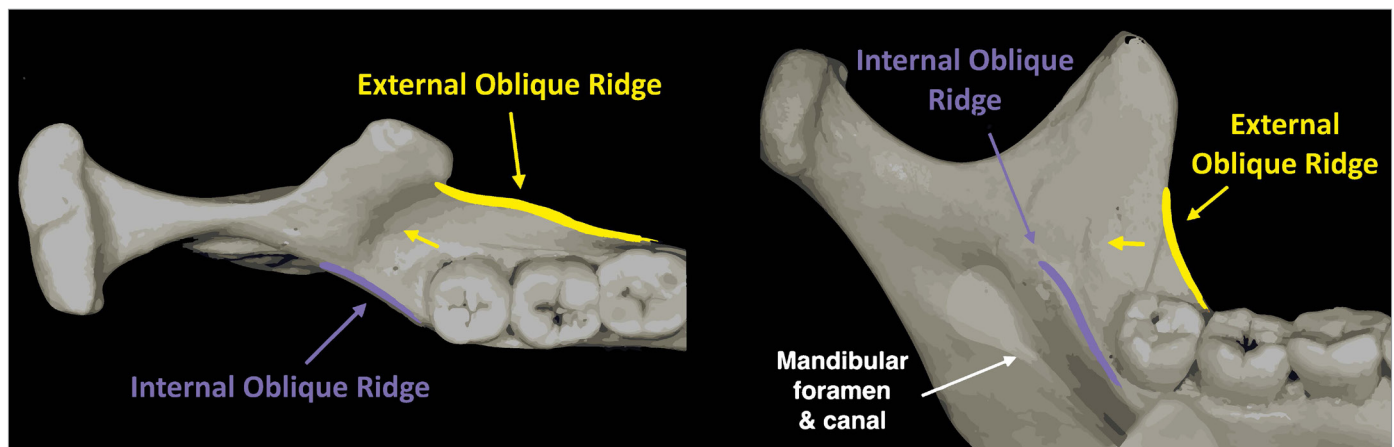


Figure 9. Positioning of mandibular Ramus Screw



of the thick and mobile mucosa in the ramus area, predrilling is not applicable for ramus screws. The risk of fracture is minimized by using stainless steel screws and increasing the diameter. Increasing the length of the screw renders it more susceptible to fracture; however, there is no case report up to date indicating fracture in a ramus screw.

The main concern should be the failure of the screw in a challenging area like the mandibular ramus (39). Based on the previous studies, the rate of failure of extra-alveolar implants is approximately the same with osseointegrated implants (less than 5%), and this rate is significantly lower compared to the failure rates of interradicular mini implants (45).

The success rates of interradicular temporary anchorage devices ranges between 57% and 95% in different studies, with a mean success rate of 84% (46). The success rate of mandibular buccal shelf screws is found to be 92.8% (47).

In the study of Chang et al. (39) in which they evaluated the success and failure rates of ramus screws on 37 patients, only two screws failed to serve as an adequate anchorage for molar uprighing. Failures occurred due to soft tissue hyperplasia related to poor oral hygiene.

## CONCLUSION

Mandibular molar uprighing leads to the normalization of functional and periodontal occlusion, enabling the roots to be positioned perpendicular to the occlusal plane and resist the occlusal forces easily. Depending on the severity of inclination or impaction, there are various surgical and orthodontic treatment alternatives. With the development of miniscrews and skeletal anchorage techniques, molar uprighing is facilitated with more predictable results and less side effects. Lately, the use of extra-alveolar temporary anchorage devices, such as mandibular ramus screws, enabled the uprighing of horizontally and deeply impacted mandibular molars that were considered impossible before.

**Peer-review:** Externally peer-reviewed.

**Author Contributions:** Supervision - E.Ö., G.M.; Design - İ.T., E.Ö., G.M.; Resources - İ.T., E.Ö., G.M.; Materials - İ.T., E.Ö., G.M.; Data Collection and/or Processing - İ.T., E.Ö., G.M.; Analysis and/or Interpretation - İ.T., E.Ö., G.M.; Literature Search - İ.T., E.Ö., G.M.; Writing Manuscript - İ.T., E.Ö., G.M.; Critical Review - İ.T., E.Ö., G.M.

**Conflict of Interest:** The authors have no conflict of interest to declare.

**Financial Disclosure:** The authors declared that this study has received no financial support.

## REFERENCES

- Grover PS, Lorton L. The incidence of unerupted permanent teeth and related clinical cases. *Oral Surg Oral Med Oral Pathol* 1985; 59: 420-5. [CrossRef]
- Owen, A.H.III: Early surgical management of impacted mandibular second molars. *J Clin Orthod* 1998; 32: 446-50.
- Cho SY, Ki Y, Chu V, Chan J. Impaction of permanent mandibular second molars in ethnic Chinese schoolchildren. *J Can Dent Assoc* 2008; 74: 521.
- Bishara SE, Ortho D, Burkey PS. Second molar extractions: a review. *Am J Orthod* 1986; 89: 415-24. [CrossRef]
- Frank CA. Treatment options for impacted teeth. *J Am Dent Assoc* 2000; 131: 623-32. [CrossRef]
- Chang CH, Lin JS, Roberts WE. Ramus screws: the ultimate solution for lower impacted molars. *Semin Orthod* 2018; 24: 135-54. [CrossRef]
- Frazier-Bowers SA, Simmons D, Koehler K, Zhou J. Genetic analysis of familial non-syndromic primary failure of eruption. *Orthod Craniofac Res* 2009; 12: 74-81. [CrossRef]
- Sawicka M, Racka-Pilszak B, Rosnowska-Mazurkiewicz A. Uprighting partially impacted permanent second molars. *Angle Orthod* 2007; 77: 148-54. [CrossRef]
- Eckhart JE. Orthodontic uprighing of horizontally impacted mandibular second molars. *J Clin Orthod* 1998; 32: 621.
- Kravitz ND. Treatment with the mandibular Arnold expander. *J Clin Orthod* 2014; 48: 689.
- Proffit W, Fields H. Contemporary Orthodontics. 5th edition. Elsevier Health Sciences, 2014.
- Kravitz ND, Yanosky M, Cope JB, Silloway K, Favagehi M. Surgical Uprighting of Lower Second Molars. *J Clin Orthod* 2016; 50: 33-40.
- Ritchey B, Orban B. The crests of the interdental alveolar septa. *J Period* 1953; 24: 75-87. [CrossRef]
- Shellhart WC, Oesterle LJ. Uprighting molars without extrusion. *J Am Dent Assoc* 1999; 130: 381-5. [CrossRef]
- Zachrisson BU, Bantleon HP. Ask an expert: Optimal mechanics for mandibular molar uprighing. *World J Orthod* 2005; 6: 80-7.
- Winter GB. Impacted mandibular third molars. St Louis: American Medical Book Co.; 1926. p. 241-79.
- Pell GJ, Gregory BT. Impacted mandibular third molars: classification and modified techniques for removal. *Dent Digest* 1933; 39:330-8.
- Huang C, Su BCW, Chang CH, Roberts WE. Asymmetric Class II Malocclusion Acquired from Early Loss of a LR6 and UL Primary Canine: Reverse the Etiology and Align a Horizontally Impacted LR8 with a Ramus Bone Screw. *J Digit Orthod* 2018; 50: 26-43.
- Lin SY, Chang C, Roberts WE. Simple mechanics to upright horizontally impacted molars with ramus screws. *Orthod J Nepal* 2016; 5: 42-7. [CrossRef]
- Tinerfe TJ, Blakey GH. Oral and maxillofacial surgery. Saunders, Philadelphia 2000.
- Orton-Gibbs S, Crow V, Orton HS. Eruption of third permanent molars after the extraction of second permanent molars. Part 1: assessment of third molar position and size. *Am J Orthod Dentofacial Orthop* 2001; 119: 226-38. [CrossRef]
- Lindh T. Should we extract teeth to avoid tooth-implant combinations? *J Oral Rehab* 2008; 35: 44-54. [CrossRef]
- Pogrel MA. The surgical uprighing of mandibular second molars. *Am J Orthod Dentofacial Orthop* 1995; 108: 180-3. [CrossRef]
- Isidor F, Karring T, Nyman S, Lindhe J. The significance of coronal growth of periodontal ligament tissue for new attachment formation. *J Clin Period* 1986; 13: 145-50. [CrossRef]
- Padwa BL, Dang RR, Resnick CM. Surgical uprighing is a Successful Procedure for Management of Impacted Mandibular Second Molars. *J Oral Maxillofac Surg* 2017; 75: 1581-90. [CrossRef]
- Melsen B, Fiorelli G, Bergamini A. Uprighting of lower molars. *J Clin Orthod* 1996; 30: 640-5.
- Moro N, Murakami T, Tanaka T, Ohto C. Uprighting of impacted third molars using brass ligature wire. *Austr Orthod J* 2002; 18: 35-8.
- Burch JG, Bagci B, Sabulski D, Landrum C. Periodontal changes in furcations resulting from orthodontic uprighing of mandibular molars. *Quintessence Int* 1992; 23: 509-13.



29. Raveli TB, Raveli DB, de Mathias Almeida KC, Pinto ADS. Molar uprighing: A Considerable and safe decision to avoid prosthetic treatment. *Open Dent J* 2017; 11: 466-75. [\[CrossRef\]](#)
30. Costa A, Raffaini M, Melsen B. Miniscrews as orthodontic anchorage: a preliminary report. *Int J Adult Orthodon Orthognath Surg* 1998; 13: 201-9.
31. Melo AC, Duarte da Silva R, Shimizu RH, Campos D, Andrighetto AR. Lower molar uprighing with miniscrew anchorage: direct and indirect anchorage. *Int J Orthod Milwaukee* 2013; 24: 9-14.
32. Magkavali-Trikka P, Emmanouilidis G, Papadopoulos MA. Mandibular molar uprighing using orthodontic miniscrew implants: a systematic review. *Prog Orthod* 2018; 19: 1-8. [\[CrossRef\]](#)
33. Lee KJ, Park YC, Hwang WS, Seong EH. Uprighting mandibular second molars with direct miniscrew anchorage. *J Clin Orthod* 2007; 41: 627-35.
34. Roberts WE, Marshall KJ, Mozsary PG. Rigid endosseous implant utilized as anchorage to protract molars and close an atrophic extraction site. *Angle Orthod* 1990; 60: 135-52.
35. Park HS, Kyung HM, Sung JH. A simple method of molar uprighing with microimplant anchorage. *J Clin Orthod* 2002; 36: 592-6.
36. Nęcka A, Skrzypczyński J, Antoszevska J. Miniscrew-anchorage in treatment of impacted second molar in mandible - case report. *Dent Med Prob* 2010; 47: 379-83.
37. Nienkemper M, Ludwig B, Kanavakis G, Pauls A, Wilmes B, Drescher D. Uprighting mesially impacted lower third molars with skeletal anchorage. *J Clin Orthod* 2016; 50: 420-6.
38. Lin JJ. The wisdom of managing wisdom teeth-Part III. Methods of molar uprighing. *Int J Orthod Implantol* 2011; 24: 4-11.
39. Chang C, Lin SY, Roberts WE. Forty consecutive ramus bone screws used to correct horizontally impacted mandibular molars. *Int J Orthod Implantol* 2016; 41: 60-72.
40. Roberts WE. Rigid implant anchorage to close a mandibular first molar extraction site. *J Clin Orthod* 1994; 28: 693-704.
41. Kanomi R. Mini implant for orthodontic anchorage. *J Clin Orthod* 1997; 31: 763-7.
42. Liou EJ, Pai BC, Lin JC. Do miniscrews remain stationary under orthodontic forces? *Am J Orthod Dentofacial Orthop* 2004; 126: 42-7. [\[CrossRef\]](#)
43. Lim HJ, Eun CS, Cho JH, Lee KH, Hwang HS. Factors associated with initial stability of miniscrews for orthodontic treatment. *Am J Orthod Dentofacial Orthop* 2009; 136: 236-42. [\[CrossRef\]](#)
44. Lin JJ. 2 mm bone screw vs MIA. *Int J Ortho Implantol* 2008; 9: 1-5.
45. Miyawaki S, Koyama I, Inoue M, Mishima K, Sugahara T, Takano-Yamamoto T. Factors associated with the stability of titanium screws placed in the posterior region for orthodontic anchorage. *Am J Orthod Dentofacial Orthop* 2003; 124: 373-8. [\[CrossRef\]](#)
46. Viwattanatipa N, Thanakitcharu S, Uttraravichien A, Pitiphat W. Survival analyses of surgical miniscrews as orthodontic anchorage. *Am J Orthod Dentofacial Orthop* 2009; 136: 29-36. [\[CrossRef\]](#)
47. Chang C, Liu SS, Roberts WE. Primary failure rate for 1680 extra-alveolar mandibular buccal shelf mini screws placed in movable mucosa or attached gingiva. *Angle Orthod* 2015; 85: 905-10. [\[CrossRef\]](#)